OPTHALMOLOGY

DISORDERS

MAIN OBJECTIVE

To promote health, prevent illnesses diagnose and manage patients suffering from common ophthalmology disorders.

SPECIFIC OBJECTIVE

- Review of anatomy and physiology
- Recognize signs and symptoms of common eye conditions.
- Manage patients suffering from common eye problems.
- Coordinate management of patients suffering from severe and complicated eye problems in hospital.
- Coordinate rehabilitation of patients suffering from severe and complicated eye conditions.

DEFINITION OF TERM

- **Diplopia:** Condition in which a single object is perceived as two; also called double vision
- **Amblyopia:** Dullness or obscurity of sight for no apparent organic reason, therefore not correctable with glasses or surgery. Sometimes called a lazy eye, wherein one eye becomes dependent on the other eye to focus, usually developed in early childhood.
- **Anterior chamber:** Space between the cornea and the crystalline lens , which contains aqueous humor.

DEFN.. CONTINUED

- **Aphakia:** Absence of the lens of the eye
- **Aqueous humor:** Transparent fluid occupying the anterior chamber and maintains eye pressure.
- **Bifocals:** Lenses containing two focal lengths, usually arranged with the focus for distance above and near focus below
- Limbus: Thin area that connects the cornea and the sclera.
- Nearsighted: Common term for myopia
- Ophthalmologist: An ophthalmologist is either a medical doctor.

DEFN…. CONTINUED

- Ophthalmoscope: Instrument used to examine the interior of the eye: it consists of a perforated mirror arranged to reflect light from a small bulb into the eye.
- Tonometry: Procedure for the measurement of intraocular pressure. A test for glaucoma.
- Ophthalmoscopy: Examination of the internal structures of the eye using an illumination and magnification system.

DEFN…. CONTINUED

- **Diopter:** Unit of measure of the refractive power.
- Fundus: Furthest point at the back of the eye, consisting of the retina, choroid, sclera, optic disc and blood vessels, seen by means of the ophthalmoscope.
- Hyperopia: Also called *farsightedness*
- Iridotomy: Treatment for closed-angle glaucoma

DEFN…. CONTINUED

- Keratectomy: Surgical removal of cornea tissue.
- Keratitis: Inflammation of the cornea
- Keratotomy: Surgical incision (cut) of the cornea
- Keratoconous: Rare, serious, degenerative corneal disease, in which the cornea thins and assumes the shape of a cone.
- Keratoplasty: Surgical reshaping of the cornea.

ANATOMY AND PHYSIOLOGY REVIEW

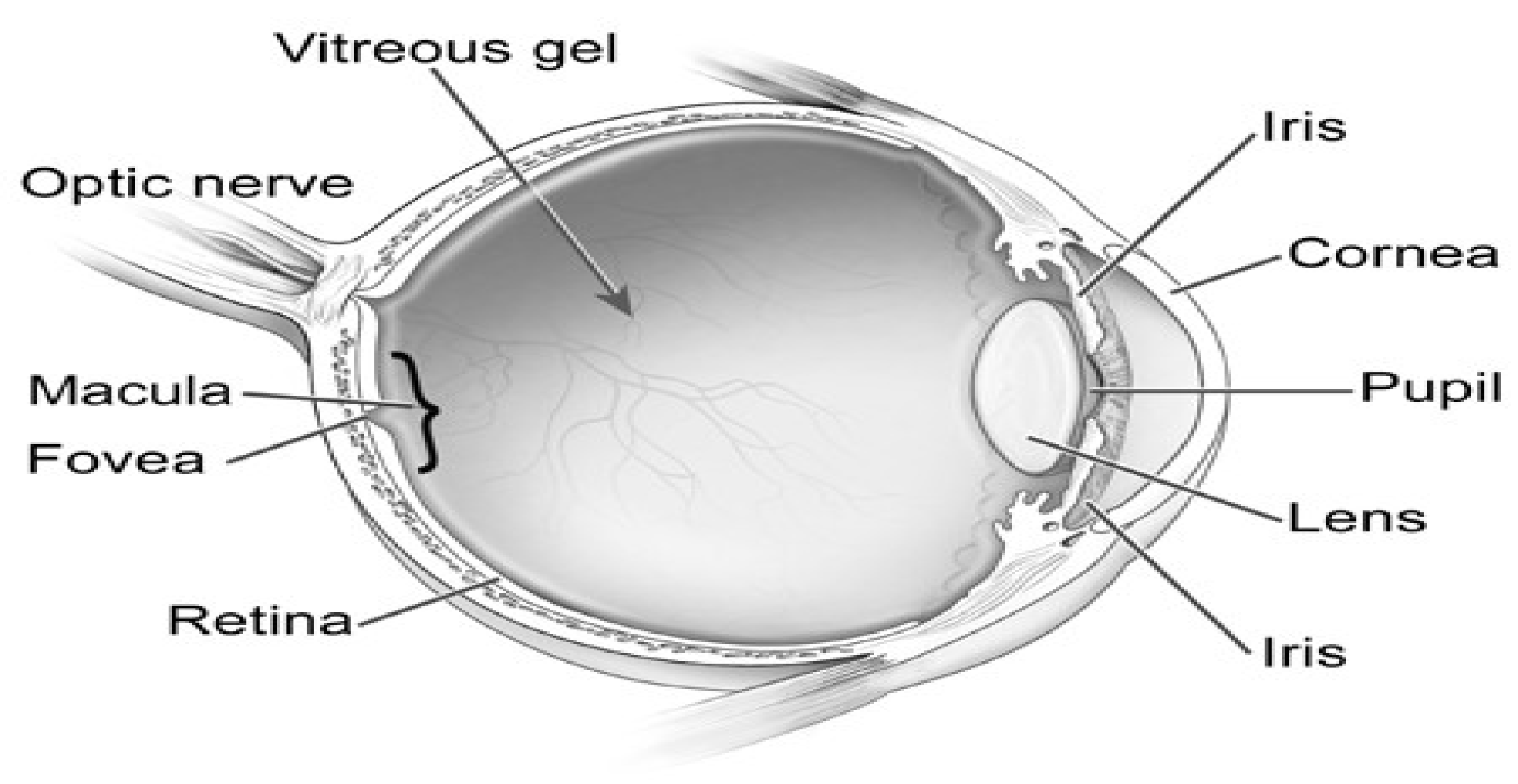

THE EYEBALL

- **Sclera**
- It’s the white part of the eye
- The sclera is a dense white tissue made of collagen fibers. It is similar to the tendons and ligaments that hold our skeleton together.
- **FUNCTIONS**
- It functions as the “skeleton” of the eye.

CORNEA

It’s a transparent structure covering the iris

It has five layers form the anterior to posterior

Corneal epithelium:

- Its an exceedingly thin multicellular epithelial tissue layer of fast-growing and easily regenerated cells, kept moist with tears. The epithelial cells get their oxygen mainly from tears.
- It is continuous with the conjunctival epithelium, and is composed of about 6 layers of cells which are shed constantly on the exposed layer and are regenerated by multiplication in the basal layer.

BOWMAN'S LAYER

(also known as the *anterior limiting membrane*) it is a tough layer composed of collagen mainly type I collagen that protects the corneal stroma.

Descemet's membrane

- it is a thin acellular layer that serves as the modified basement membrane of the corneal endothelium, from which the cells are derived. This layer is composed mainly of collagen type IV fibrils, less rigid than collagen type I fibrils.

Corneal stroma

- A thick, transparent middle layer which makes up most of the cornea, and consists of layers of parallel collagen fibres lying at right-angles to each other keratocytes, which are the cells for general repair and maintenance This very regular structure is important for the transparency of the cornea.
- If the arrangement of fibres is disorganized, there will be a loss of clarity, visible as a cornea scar.

CORNEAL ENDOTHELIUM:

- This single layer of cells pumps water out of the cornea, keeping it dry and transparent. Unlike the corneal epithelium the cells of the endothelium do not regenerate. Instead, they stretch to compensate for dead cells which reduces the overall cell density of the endothelium, which has an impact on fluid regulation. The endothelial cells cannot be replaced once they have been damaged. They obtain glucose and oxygen from the aqueous humour

MIDDLE VASCULAR LAYER

- This layer is also called the uvea, or uveal tract. All three uveal tissues are pigmented and vascular.
- **Choroid:**
  - The choroid is a thin layer of tissue lying between the retina and sclera.
  - Its pigment helps to absorb light after it has passed through the retina.
  - The high flow of blood through the choroid means that it can supply oxygen to the outer part of the retina.

2 Ciliary body:

- The ciliary body lies between the edge of the choroid, and the iris.
- It contains the ciliary muscle, which alters the focus of the eye by changing the shape of the lens, to which it is attached by the zonules.
- The surface of the ciliary body consists of tiny folds and processes, the ciliary processes.
- A single layer of cells on the surface of the ciliary processes, the ciliary epithelium, secretes aqueous humour.
-

Iris:

- The iris is a ring of pigmented tissue that controls the amount of light entering the eye.
- The hole in the centre of the iris is the pupil and all light entering the eye must pass through this opening.
- The iris, by contracting the circular sphincter muscle at the pupil margin, makes the pupil smaller.
- Contraction of the radial dilator muscle fibres enlarges the pupil.
- The pupil constricts in bright light, and when looking at near objects.

3. INNER LIGHT-SENSITIVE LAYER

- **Retina:**
- The retina is the light sensitive part of the eye. It can be divided into two parts.

Outer photoreceptor layer:

- This contains the cells that respond to light.

THERE ARE TWO TYPES OF PHOTORECEPTOR CELL, RODS AND CONES

Rods	**Cones**
Respond to dim light	Respond to bright light
Monochrome (B&W) vision	Colour vision
Peripheral vision	Central detailed vision

- The photo-receptors contains a chemical called retinol, which changes when it is exposed to light, Retinol is Vitamin A.
- At the centre of the retina is an area called the macula.
- This part of the retina does not contain any rods, or the nerve fibre layer.

It is responsible for the detailed central vision used for reading. The photoreceptor layer receives oxygen from the choroid.

- ✓ **Nerve fibre layer:**

When light hits a photoreceptor cell, the cell transmits an electrical signal, which is carried down the nerve fibres until it reaches the brain. The nerve fibres all meet at the optic disc, where they join together to form the optic nerve. The nerve fibre receives its blood supply from blood vessels which enter the eye through the optic disc.

CONTENTS OF THE EYE

Vitreous Humour

The vitreous is a transparent gel, similar to the white of an egg. It is fixed to the most anterior part of the retina, the ora serrata. Elsewhere, it is in contact with the retina, but is not attached to it.

Lens

The lens is composed of a central nucleus, surrounded by the cortex. It is enclosed in a thin membrane, the capsule. The lens is attached to the ciliary body, just behind the iris, bthe fine fibres of the zonule. As the ciliary muscle contracts, the zonular fibres relax, allowing the lens to become fatter, and changing the focal point of the eye

3. Aqueous

- Aqueous means watery, and the aqueous humour is composed of water and a little salt. It is produced by the ciliary body.
- From the ciliary body it circulates around the lens, through the pupil, and into the anterior chamber.
- It slowly passes out of the eye through the trabecular meshwork.

- This is a fine network of fibrous tissue that lies in a ring around the anterior chamber between the cornea and the iris.
- Aqueous soaks through it gradually, because the continuous production of aqueous by the ciliary body causes the pressure of fluid inside the eye to rise until the aqueous is forced out through the trabecular meshwork.
- Once through the trabecular meshwork, the aqueous enters the canal of schlemm, which simply collects aqueous as it leaves the anterior chamber.

- From the canal of schlemm, the aqueous drains freely into veins lying under conjunctiva.
- The circulation of aqueous is very important. It provides oxygen for the lens and the corneal endothelium.
- The pressure produced by the continual production of aqueous and the resistance to outflow of the trabecular meshwork is the Intra-Ocular Pressure, or IOP. The normal IOP is 10 – 21 mmHg.

.

THE EYELIDS

- The globe is protected by two folds of skin and mucous membrane, the eyelids.
- The medial and lateral angles of the lids are called the medial and lateral canthus
- The lids are divided into two parts:-

1. Anterior Lamella

Skin: The skin is thin and almost without hairs.

Orbicularis: This muscle runs around the eyelids in a circle. Contraction of the orbicularis muscle closes the eye. It is supplied by the Facial or 7th nerve.

Lashes: These special hairs grow on the lateral 5/6 of the lids. The help to protect the eye.

POSTERIOR LAMELLA

- **Conjunctiva:** The conjunctiva is a thin mucous membrane that starts at the lid margin, covers the back of the lid, and the surface of the sclera. It stops at the limbus.
- It contains mucous glands which are essential for the tear film

TARSAL PLATE:

- The tarsal plate is the skeleton of the lids.
- It is made of fibro-cartilage. The conjunctiva is firmly stuck to its inner surface, so it moves easily over the eye.
- The tarsal plates contain meibomian glands which produce an oily secretion that slows the evaporation of the tears. The upper tarsal plate is supported by the levator muscle. Contraction of this muscle opens the eye, and is controlled by the oculomotor, or 3rd nerve.

THE ORBIT

- The Orbit is the bony cavity that contains the eyeball, and its associated structures. The orbit is shaped like a pyramid, with four triangular sides.
  - Medial Wall: Ethmoid bone
  - Lateral Wall: Zygomatic bone
  - Floor: Maxillary bone
  - Roof: Frontal bone
  - Apex: Sphenoid bone.
- All these bones, except the zygoma, contain large empty spaces, lined with mucous membrane, and opening into the nose. These are called para-nasal sinuses.

ORBITAL CONTENTS

1. **Muscles**

- There are seven muscles in the orbit.

a) **Rectus Muscles**

- All the rectus arise from the apex of the orbit, and are attached to the eye about 5-6 mm in front of the equator.
- **b) Oblique Muscles**
- **Superior oblique** – this muscle arises from the apex with the other muscles, but then passes through a “pulley” or trochlea on the medial wall of the orbit. The tendon then runs backwards from the trochlea to attach to the eye under the superior rectus. Supplied by the Trochlear, 4th nerve.

Inferior oblique – this muscle arises from the medial floor of the orbit, and passes under and behind the eye. Supplied by 3rd nerve.

Both the oblique muscles are attached to the eye behind the equator. The superior oblique makes the eye look down, and the inferior oblique makes the eye look up.

c) Levator Muscle

The levator arises from the apex of the orbit, and is attached to the upper tarsal plate. It is supplied by the oculomotor, 3rd nerve, and it opens the eye by raising the upper lid.

2) NERVES

- The orbit contains the following nerves:-
  - **2nd – Optic nerve** – carries visual information from the retina to the brain. Covered in meninges, and surrounded by CSF.
  - **3rd – Oculomotor nerve** – controls extra-ocular muscles, pupil sphincter, and ciliary muscle.
  - **4th – Trochlear nerve** – controls superior oblique muscle.
  - **5th – Ophthalmic nerve** – this is one branch of the trigeminal nerve. It supplies touch and pain sensation to t he eye and upper lid.
  - **6th – Abducens nerve** – controls the lateral rectus muscle

3) LACRIMAL GLAND & DUCTS

- The lacrimal gland produces tears, which protect and lubricate the eye. It lies in the upper lateral quarter of the orbit. The gland is divided into two parts by the levator muscle. Half of the gland lies above the levator, next to the roof of the orbit, and half lies below the levator, next to the conjunctiva.
- The gland secretes tears through 10-20 tear ducts that enter the conjunctival sac through the upper fornix.
- After the tears have spread across the eye, they drain away through the puncta.

- These are two little holes in the upper and lower lid, about 5mm from the media canthus. From the puncta, two very narrow ducts, the canaliculi, carry the tears to the naso-lacrimal sac.
- The naso lacrimal sac empties into the naso-lacrimal duct, which lies in the lateral wall of the nose. The tears finally drain into the nose through an opening in the side of the nasal cavity.

4) OTHER CONTENTS

- The remaining space within the orbit is filed with fat. This forms a cushion on which the eye rests.

The Visual Pathway

- The optic nerve leaves the orbit through the optic foramen. The optic nerves then meet at the optic chiasm, which lies just above the pituitary gland. At the chiasm, the optic nerve fibres from the nasal retina cross over to the opposite side of the brain, while those from the temporal retina stay on the same side.

After the chiasm, the nerve fibres form the optic tract. This is composed of nerve fibres from both eyes. Most of the nerve fibres in the optic tract go to the lateral geniculate nucleus in the thalamus, but a small number go to the 3rd nerve nucleus. From the thalamus, the nerve fibres go to the visual cortex, at the back of the brain, in the occipital lobe. The 3rd nerve controls the pupil light reflex, which means that when a bright light shines into one eye, the sphincter muscles of both eyes contract, making the pupils smaller.

VISUAL ACUITY

- Visual acuity (V.A) is a measure of the patient's ability to see detail at a specified distance. It is the first and most important part of any examination of an eye patient.
- It is usually tested with a VA chart.
- Two types:-
  - Letters (Snellen) – Patient must be literate.
  - E chart – 25% chance of guessing correctly.
- VA is usually quoted as two numbers, one above the other, e.g. 6/6, 6/18, 6/5.

VISUAL ACQUITY… CONTD

- VA measurement is based on a theoretical normal person. The bottom number of the VA is the distance at which a normal person should be able to see the letters.
- The top number indicates the distance at which the patient can read these letters.
- 6/6 means that the line of letters which can be seen by the patient at 6 metres corresponds to the size of letter that can be seen by a theoretically normal person at 6 metres. A vision of 6/6 is normal vision.

VISUAL ACQUITY… CONTD

- 6/18 means that the line of letters which can be seen by the patient at 6 metres corresponds to the size of letter that can be seen by a theoretically normal person at 18 metres. A vision of 6/18 is a little worse than normal.

6/5 means that the line of letters which can be seen by the patient at 6 metres corresponds to the size of letter that can be seen by a theoretically normal person at 5 metres. A vision of 6/5 is a little better than normal.

- What does 6/60 mean?
- What does 3/60 mean?

VISUAL ACQUITY…CONTD

- The VA is tested by covering one eye, and testing the other eye, so that the vision is measured in each eye individually. The patient should stand 6 metres from the chart, which should be well illuminated, and on a dark background.
- If the patient cannot see the top letter on the chart, VA is tested by:-

✓ Bringing the patient closer to the chart.

✓ Finger counting at different distances e.g. CF 5m, CF 2m.

✓ Hand Motions e.g. HM. Examiners hand is passed slowly in front of the patient's eyes.

✓ Perception of light e.g. PL

If the eye has No perception of light it is recorded as NPL. Measuring the VA does not begin and end with the E-chart, you can begin to assess the VA as soon as you see the patient. Can he walk unaided, or is he led? Does he know where to sit? Can he tell staff from patients?

A VA of less than 3/60 means that the patient is blind by the WHO definition of blindness. However, different people require different standards of vision. A farmer can grow food successfully with a VA of 6/60, but an eye doctor needs 6/6. Most everyday tasks are easily accomplished with a VA of 6/18.

A reduced VA may be the result of:-

- ✓ Blindness
- ✓ Malingering
- ✓ Failure to comprehend, or to co-operate in, the test.
- ✓ Uncorrected refractive error.

When the vision is less than 6/18, it should be checked with a pinhole, if no cause for the reduced VA can be found. A pinhole compensates for uncorrected refractive errors. A normal VA does not exclude serious eye disease. The VA tests only the macular vision, and not the remainder of the retina, and or the peripheral visual field.

OPHTHALMOLOGY ABBREVIATIONS

LP, LPO - Light perception, light perception only

A/C or AC - Anterior chamber

LR - Lateral rectus

ACG -Angle closure glaucoma

ALPC - Argon laser photocoagulation (often for diabetic macular edema for pupil dilation

CONT'D.

HM - Hand motion vision

SPK - Superficial punctate keratitis

ICCE - Intracapsular cataract extraction

IO - Inferior oblique

IOL - Intraocular lens

IOP - Intraocular pressure

VA - Visual acuity
IR - Inferior rectus
VF - Visual field
Vit - Vitreous
VTX – Vitrectomy
SR - Superior rectus
PSC - Posterior subcapsular cataract

CONT'D.

PC – posterior chamber

PVD - Posterior vitreous detachment

RD - Retinal detachment

RP - Retinitis pigmentosa

NLP - No light perception

AMD - Age-related macular degeneration

APD - Afferent pupillary defect

CF - Count fingers visual acuity

MANAGEMENT OF A PATIENT WITH EYE PROBLEMS.

- This should be done using nursing process i.e. assessment, planning, implementation and evaluation.
- **ASSESSMENT**
- History taking about:-
  - Difficulty in reading.
  - Blurred vision.
  - Double vision(diplopia).
  - Burning sensation of the eyes.
  - Watering of the eyes.

- Isolated areas of loss of vision.
- Determine whether the problem is affecting one eye or both(unilateral or bilateral)
- Ascertain the patient’s general ocular conditions e.g.
- Does he/she use glasses, contact lenses or any other assistive devices.
- Any previous eye check –up and when.
- Any problem focusing at close range.
- Any problem differentiating colours.
- Any problem watching TV

CONT'D.

- Any eye trauma ,current or past.
- Any history of eye infections.
- Any eye problem existing in the patients family.
- Determine the patient's understanding of eye care and treatment.

EXAMINATION OF THE EYE

Should be systematic from the lid to the optic nerve.

SOME NURSING DIAGNOSIS

1. Pain or altered comfort related to pressure in the eye or eye injury as verbalised by the patient.
2. Fear/anxiety related to impaired vision, or partial loss of sight evidenced by patient asking questions e.g. will I be able to see again or be blind.
3. Alteration in visual perception related to ocular trauma/inflammation, infection, tumour or degeneration evidenced by patient inability to read, walk without assistance etc.

NURSIGN DIAGNOSIS…CONTD

- 4. Self care deficit related to impaired vision/ limited knowledge regarding eye care evidenced by patient asking for assistance frequently.
- 5. Social isolation related to limited ability to participate in social and recreational activities secondary to impaired vision evidenced by disinterest in the surrounding

PLANNING

GOALS /OBJECTIVES OF THE MANAGEMENT

- To relief pain.
- To allay anxiety.
- Prevention of further visual deterioration.
- Patient be able to accomplish self care activities including application of medication.
- Avoidance of social isolation.

INTERVENTION

1. Relief pain by:-

- An eye patch to inhibit the eye movement.
- The uncovered should also rest as the eyes move together in the same direction.
- Maintain dim light as bright light aggravates pain in many eye conditions.
- Give prescribed analgesics e.g. paracetamol 1g.

EVALUATION

- Pt. verbalizes reduced pain.
- P. Have reduced eye activity.
- Pt participates in self-care activities.
- Pt accepts treatment and carries out appropriate recommendations e.g. able to report any abnormal signs.

GENERAL CARE FOR PATIENT UNDERGOING SURGERY

PRE-OPERATIVE NURSING MANAGEMENT

- Explain to the patient about the nature of the operation inorder to get an informed consent.
- Instill eye drops as prescribed e.g. atropine drops to dilate the pupil if cataract extraction, pilocarpine to constrict the pupil in glaucoma or antibiotic for prophylaxis.
- Shave the eye rashes to keep the area clean and prevent foreign body in the eye with scissors covered with petroleum jelly.
- If the operation will be under GA starve for six hours.
- Wash the face of the patient and address any concern to allay anxiety

POST-OPERATIVE

1. If both eyes are padded, place the patient in supine position with a small pillow under his head and another pillow on each side of the head to keep it still.
2. Set the side rails to give the patient a sense of security and to avoid falling.
3. Encourage the patient to seek for help instead of moving.

Incase the operation was done under local anaesthesia, you should inform the ophthalmologist if the patient has excessive pain or the dressing is disturbed.

5. The light should be dim as bright light aggreviates pain and delays healing.

CONT'D.

6. Orientate the patient constantly to reality as they have a sense of floating and any one entering the patient's room should identify themselves to avoid startling the patient.

7. Assist the patient in performing activities of dairy living to keep him/her clean and comfortable while encouraging him/her to carryout as much as possible, to promote a sense of self sufficiency.

8. Give a well balanced diet to

CONT'D….

9. Encourage the patient to ambulate but should alternate with period of rest to prevent complications and enhance healing.

10. To rest the eye and prevent pressure the patient is not allowed to read, shaving beards for men, smoking and also cautioned against rubbing their eyes.

11. They should wash their hands before instilling any medication to prevent infection and medications are

CONTD….

- 12. To promote activities and avoid social isolation the patient to have visitors, express his feelings and keep their mind occupied e.g. group therapy.
- 13. When permanent blindness is apparent the patient should be re-educated and special training offered in order to ultilise their remaining potentials.

BLINDNESS

- It is a major worldwide public health problem.
- There are about 30,000,000 blind people in the world, of whom 28,000,000 live in third world countries.
- In Kenya, about 1% of the population is blind, approx. 220,000 people.
- In parts of Africa, particularly the richer and more urbanized areas, the prevalence if blindness is less.
- In most other regions, especially where trachoma or onchocerciasis are common, the prevalence of blindness is higher e.g. nearly 5% higher in southern Sudan.
- N/B: The number of blind people increases as the population increases.

GROUPS OF BLINDNESS

Blind people can be divided into three groups:

- **Economic blindness**

one is unable to see enough to perform normal work. The VA will depend on the work being done. This affects the community at large.

- **Navigational blindness**

Unable to walk unaided in unfamiliar surroundings. Usually a VA OF 3/60. This is the WHO definition of blindness.

- **Social blindness**

Unable to dress, feed or look after himself. They totally depend on friends and other family members. VA usually HM or worse.

CAUSES OF BLINDNESS

- Cataract
- Trachoma
- Glaucoma
- Diabetic retinopathy.
- Onchocerciasis
- Xerophthalmia.

Other causes e.g. traditional eye medicine.

ORBITAL

DISORDERS

- The orbital bone
  - The eye socket
  - Formed by:
    - Cheekbone
    - Forehead
    - Temple
    - Side of nose
  - Eye is cushioned within orbit by pads of fat
- Lacrimal gland
  - Produces tears
  - Tears drain through the nasolacrimal duct

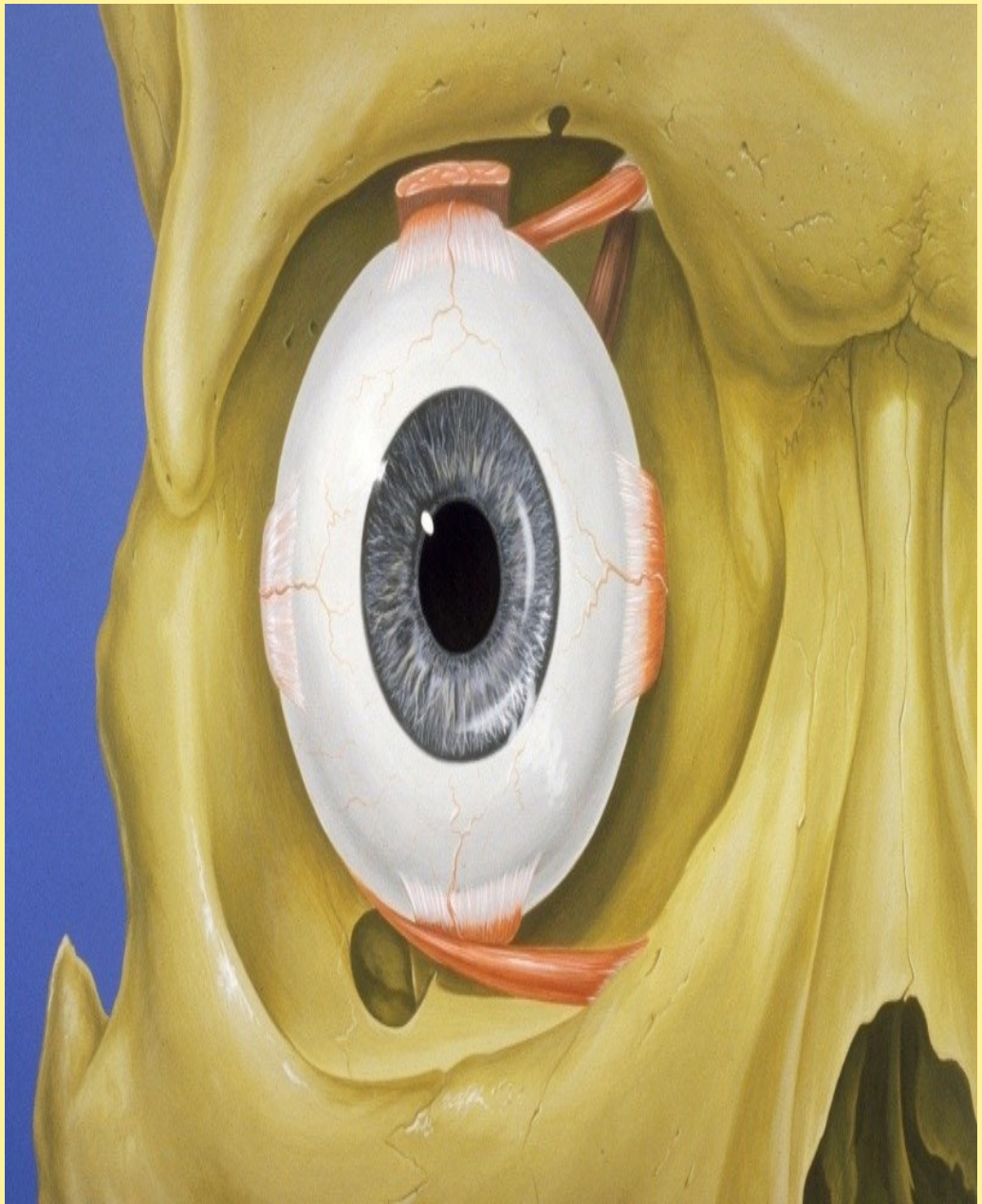

MANAGEMENT OF COMMON OCULAR CONDITIONS

ORBIT

1. The orbit is the bony socket containing the eye and its surrounding structures, e.g. lacrimal gland, extra ocular muscles etc.
2. Diseases in the orbit causes displacement of the eyeball.
3. If the eye is pushed forward, it is called proptosis and it is the commonest symptom of orbital disease.

COMPLICATION OF ORBITAL DISEASES

BLINDNESS which is caused by either:

1. Exposure keratopathy – the eyeball is so proptosed that the lid cannot close over it.

TREATMENT

- Tarsorrhaphy, and refer for orbital surgery.

OPTIC NERVE COMPRESSION

Pressure on the nerve within the orbit leads to optic atrophy.

TREATMENT

- High dose systemic steroids, and refer urgently for orbital surgery.

N/B: Malignant disease in the orbit causes death by invading the brain, or by distant metastasis.

EXAMINATION OF THE ORBIT DISEASES

Note the following;

1. Displacement of the globe – note how far the globe has been displaced, and in what direction. Has it been pushed up, down or sideways, or just forward.
2. Orbital mass – Feel around the orbital margin to look for a palpable mass. Check the pre-auricular lymph nodes.
3. Eye movement- look for any restriction in eye movement.
4. Exposure – check whether the patient can close the eye.
5. Pupil reaction – look for an afferent pupil defect.

ORBITAL DISEASES

ORBITAL CELLULITIS. Its usually caused by pneumococci, streptococci or staphylococci. The infection can enter the orbit through the thin walls of the surrounding sinuses.

2. From the orbit it can spread to the brain via the venous drainage of the orbit, or directly via the optic nerve and this can be fatal.

CLINICAL FETURES

- Acute pain, Swelling and fever.
- Proptosis and very inflamed eye.
- Restricted eye movement.
- The pupil may be fixed and dilated.

MANAGEMENT

1. Admit for and give high dose of intravenous antibiotics.
2. Intra-orbital abscesses may need to be drained surgically.

Delay can be fatal.

MUCOCELE

This is accumulation of mucus within the sinus due to obstruction of the sinus opening and it gradually enlarges into the orbit.

The commonly affected sinuses are frontal and ethmoid.

CLINICAL FETURES

Slow progressive Proptosis over a period of time.

The globe is displaced inferiorly and laterally.

A smooth mass can often be felt near the orbital margin.

MANAGEMENT

Refer for surgery.

The mucocele is opened and drained and a drainage inserted through the nose left insitu.

This drainage is left insitu for 6 months to prevent the mucocele from recurring.

ORBITAL TRAUMA

Injury to the orbit is usually associated with a head injury; hence,the patient's general medical condition must first be stabilized before conducting an ocular examination.

To establish the extent of ocular injury, visual acuity is assessed as soon as possible, even if it is only a rough estimate. Soft tissue orbital injuries often result in damage to the optic nerve. Major ocular injuries indicated by a soft globe, prolapsing tissue, ruptured globe, hemorrhage,and loss of red reflex require immediate surgical attention.

The signs and symptoms

- Tenderness
- Ecchymosis
- lid swelling
- **proptosis** (ie, downward displacement of the eyeball)
- hemorrhage.

Closed injuries lead to contusions with subconjunctival hemorrhage, commonly known as a *black eye*. Blood accumulates in the tissues of the conjunctiva. Hemorrhage may be caused by a soft tissue injury to the eyelid or by an underlying fracture.

MANAGEMENT

- Its usually conservative and consists of thorough inspection, cleansing, and repair of wounds.
- Cold compresses are used in the early phase followed by warm compresses.
- Hematomas that appear as swollen, fluctuating areas may be surgically drained or aspirated;
- If they are causing significant orbital pressure, they may be surgically evacuated.

severe optic nerve damage. Visual loss can be sudden or delayed and progressive.

- Immediate loss of vision after an ocular injury is usually irreversible. Delayed visual loss has a better prognosis.
- Corticosteroid therapy is indicated to reduce optic nerve swelling.
- Surgery, such as optic nerve decompression, may be performed.

ORBITAL FRACTURES

- Orbital fractures are detected by facial x-rays. Depending on the orbital structures involved, orbital fractures can be classified as blow-out, zygomatic or tripod, maxillary, midfacial, orbital apex and orbital roof fractures. Blow-out fractures result from compression of soft tissue and sudden increase in orbital pressure when the force is transmitted to the orbital floor, the area of least resistance.

The inferior rectus and inferior oblique muscles, with their fat and fascial attachments, or the nerve that courses along the inferior oblique muscle may become entrapped, and the globe may be displaced inward (ie, enophthalmos).

Computed tomography (CT) can firmly identify the muscle and its auxiliary structures that are entrapped. These fractures are usually caused by blunt small objects, such as a fist, knee, elbow, or tennis or golf balls.

Orbital roof fractures are dangerous because of potential complications to the brain. Surgical management of these fractures requires a neurosurgeon and an ophthalmologist.

The most common indications for surgical intervention are

- Displacement of bone fragments disfiguring the normal facial contours
- Interference with normal binocular vision caused by extraocular muscle entrapment
- Interference with mastication in zygomatic fracture
- Obstruction of the nasolacrimal duct.

Surgery is usually nonemergent, and a period of 10 to 14 days gives the ophthalmologist time to assess ocular function, especially the extraocular muscles and the nasolacrimal duct.

Emergency surgical repair is usually not performed unless

- the globe is displaced to the maxillary sinus.
- freeing the entrapped ocular structures
- restoring the integrity of the orbital floor.
- Cosmetic surgery for deformities of the globe

Enophthalmos may follow after 4 to 6 months, but successful repair is usually difficult.

FOREIGN BODIES

- Foreign bodies that enter the orbit are usually tolerated, except for copper, iron and vegetable materials such as those from plants or trees, which may cause purulent infection. X-rays and CT scans are used to identify the foreign body.
- Careful history taking is important, especially if the foreign body has been in the orbit for a period of time and the incident forgotten. It is important to identify metallic foreign bodies because they prohibit the use of magnetic resonance imaging (MRI) as a diagnostic tool.

- After the extent of the orbital damage is assessed, the decision is made between conservative treatment and surgical removal.
- Orbital foreign bodies are usually removed if they are superficial and anterior in location, have sharp edges that may affect adjacent orbital structures, or are composed of copper, iron, or vegetable material.

FOREIGN BODIES…. CONTD

- The surgical intervention is directed at prevention of further ocular injury and maintaining the integrity of the affected areas.
- Cultures are usually obtained, and the patient is placed on prophylactic intravenous antibiotics that are later changed to oral antibiotics.

OCULAR TRAUMA

- Ocular trauma is the leading cause of blindness among children and young adults, especially male trauma victims. The most common circumstances of ocular trauma are occupational injuries (eg, construction industry), sports (eg, baseball, basketball, racket sports, boxing), weapons (eg, air guns, BB guns), assault, motor vehicle crashes (eg, broken windshields), and war (eg, blast fragments).

OCCULAR TRAUMA…CONTD

For the non ophthalmic practitioner, initial intervention is performed in only two conditions: chemical burns, for which irrigation of the eye with normal saline solution or even plain tap water must occur immediately, and a foreign body, for which bodies are usually removed if they are superficial and anterior in location

ASSESSMENT AND DIAGNOSTIC FINDINGS

- A thorough history is obtained, particularly assessing the patient’s ocular history, such as preinjury vision in the affected eye or past ocular surgery

ASSESSMENT AND DIAGNOSIS…CONTD

.Details related to the injury that helps in the diagnosis and assessment of need for further tests include the nature of the ocular injury (ie, blunt or penetrating trauma), the type of activity causing the injury to determine the nature of the force striking the eye and whether onset of vision loss was sudden, slow or progressive.

For chemical eye burns, the chemical agent must be identified and tested for pH if a sample is available. The corneal surface is examined for foreign bodies, wounds, and abrasions, after which the other external structures of the eye are examined.

ASSESSMENT AND DIAGNOSIS… CONTD

Pupillary size, shape, and light reaction of the pupil ofthe affected eye are compared with the other eye. Ocular motility, which is the ability of the eyes to move synchronously up, down, right, and left, is also assessed.

MEDICAL MANAGEMENT
SPLASH INJURIES

Splash injuries are irrigated with normal saline solution before further evaluation. In cases of ruptured globe, cycloplegic agents (ie, agents that paralyze the ciliary muscle) or topical antibiotics must be deferred because of potential toxicity to exposed intraocular tissues. Further manipulation of the eye must be avoided until the patient is under general anesthesia.

SPLASH INJURIES ….CONTD

Parenteral, broad spectrum antibiotics are initiated. Tetanus antitoxin is administered, if indicated, as well as analgesics. (Tetanus prophylaxis is recommended for full-thickness ocular and skin wounds.) Any topical medication (eg, anesthetic, dyes) must be sterile

FOREIGN BODIES AND CORNEAL ABRASIONS

- After removal of a foreign body from the surface of the eye, an antibiotic ointment is applied, and the eye is patched. The eye is examined daily for evidence of infection until the wound is completely healed.
- Contact lens wear is a common cause of corneal abrasion. The patient experiences severe pain and **photophobia** (ie, ocular pain on exposure to light).

FOREIGN BODIES… CONTD

- Corneal epithelial defects are treated with antibiotic ointment and a pressure patch to immobilize the eyelids.
- It is of utmost importance that topical anesthetic eye drops are not given to a patient for repeated use after corneal injury because their effects mask further damage, delay healing, and can lead to permanent corneal scarring. Corticosteroids are avoided while the epithelial defect exists.

PENETRATING INJURIES AND CONTUSIONS OF THE EYEBALL

Sharp penetrating injury or blunt contusion force can rupture the eyeball. When the eye wall, cornea and sclera rupture, rapid decompression or herniation of the orbital contents into adjacent sinuses can occur. In general, blunt traumatic injuries (with an increased incidence of retinal detachment, intraocular tissue avulsion, and herniation) have a worse prognosis than penetrating injuries.

PENETRATING INJURIES ….CONTD

Most penetrating injuries result in marked loss of vision with the following signs: hemorrhagic **chemosis** (ie, edema of the conjunctiva), conjunctival laceration, shallow anterior chamber with or without an eccentrically placed pupil, **hyphema** (ie, hemorrhage within the chamber), or vitreous hemorrhage.

Hyphema is caused by contusion forces that tear the vessels of the iris and damage the anterior chamber angle. Preventing rebleeding and prolonged increased IOP are the goals of treatment for hyphema.

An eye shield is applied. Topical corticosteroids are prescribed to reduce inflammation. An antifibrinolytic agent, aminocaproic acid (Amicar), stabilizes clot formation at the site of hemorrhage. Aspirin is contraindicated.

A ruptured globe and severe injuries with intraocular hemorrhage require surgical intervention. Vitrectomy is performed for traumatic retinal detachments. Primary **enucleation** (ie, complete removal of the eyeball and part of the optic nerve) is considered only if the globe is irreparable and has no light perception.

It is a general rule that enucleation is performed within 2 weeks of the initial injury (in an eye that has no useful vision after sustaining penetrating injury) to prevent the risk of **sympathetic ophthalmia,** an inflammation created in the fellow eye by the affected eye that can result in blindness of the fellow eye.

INTRAOCULAR FOREIGN BODIES

A patient who complains of blurred vision and discomfort should be questioned carefully about recent injuries and exposures.

Patients may be injured in a number of different situations and suffer an intraocular foreign body (IOFB). Precipitating circumstances can include working in construction, striking metal against metal, being involved in motor vehicle crashes with facial injury, gunshot wounds, and grinding-wheel work.

IOFB is diagnosed and localized by slit-lamp biomicroscopy and indirect ophthalmoscopy, as well as CT or ultrasonography.

MRI is contraindicated because most foreign bodies are metallic and magnetic..

It is important to determine the composition, size, and location of the IOFB and affected eye structures. Every effort should be made to identify the type of IOFB and whether it is magnetic.

Iron, steel, copper, and vegetable matter cause intense inflammatory reactions. The incidence of endophthalmitis is also high. If the cornea is perforated, tetanus prophylaxis and intravenous antibiotics are administered. The extraction route (ie, surgical incision) of the foreign body depends on its location and composition and associated ocular injuries.

Specially designed

IOFB forceps and magnets are used to grasp and remove the foreign body. Any damaged area of the retina is treated to prevent retinal detachment.

OCULAR BURNS

Alkali, acid and other chemically active organic substances, such as mace and tear gas, cause chemical burns. Alkali burns (eg, lye, ammonia) result in the most injury because they penetrate the ocular tissues rapidly and continue to cause damage long after the initial injury is sustained. They also cause an immediate rise in IOP.

OCCULAR BURNS…CONTD

Acids (eg, bleach, car batteries, refrigerant) generally cause less damage because the precipitated necrotic tissue proteins form a barrier to further penetration and damage. burns, every minute counts.

Chemical burns may appear as superficial punctate keratopathy (ie, spotty damage to the cornea), subconjunctival hemorrhage, or complete marbleizing of the cornea.

In treating chemical Immediate tap-water irrigation should be started on site before transport of the patient to an emergency department. Only a brief history and examination are performed. The corneal surfaces and conjunctival fornices are immediately and copiously irrigated with normal saline or any neutral solution. A local anesthetic is instilled, and a lid speculum is applied to overcome blepharospasm (ie, spasms of the eyelid muscles that result in closure of the lids).

OCCULAR BURNS…CONTD

Particulate matter must be removed from the fornices using moistened, cottontip applicators and minimal pressure on the globe.

Irrigation continues until the conjunctival pH normalizes (between 7.3 and 7.6). The pH of the corneal surface is checked by placing a pH paper strip in the fornix. Antibiotics are instilled, and the eye is patched.

OCCULAR BURNS ….CONTD

The goal of intermediate treatment is to prevent tissue ulceration and promote re-epithelialization. Intense lubrication using nonpreserved (ie, without preservatives to avoid allergic reactions) tears is essential. Re-epithelialization is promoted with patching or therapeutic soft lenses. The patient is usually monitored daily for several days. Prognosis depends on the type of injury and adequacy of the irrigation immediately after exposure.

Long-term treatment consists of two phases: restoration of the ocular surface through grafting procedures and surgical restoration of corneal integrity and optical clarity.

Thermal injury is caused by exposure to a hot object (eg, curling iron, tobacco, ash), whereas photochemical injury results from ultraviolet irradiation or infrared exposure (eg, exposure to the reflections from snow, sun gazing, viewing an eclipse of the sun without an adequate

These injuries can cause corneal epithelial defect, corneal opacity, conjunctival chemosis and **injection** (ie, congestion of blood vessels), and burns of the eyelids and periocular region. Antibiotics and a pressure patch for 24 hours constitute the treatment of mild injuries. Scarring of the eyelids may require oculoplastic surgery, whereas corneal scarring may require corneal surgery.

INFECTIOUS AND INFLAMMATORY CONDITIONS. DRY EYE SYNDROME

Dry eye syndrome, or keratoconjunctivitis sicca, is a deficiency in the production of any of the aqueous, mucin, or lipid tear film components; lid surface abnormalities; or epithelial abnormalities related to systemic diseases (eg, thyroid disorders, Parkinson’s disease), infection, injury, or complications of medications (eg, antihistamines, oral contraceptives, phenothiazines).

CLINICAL MANIFESTATIONS

The most common complaint in dry eye syndrome is a scratchy or foreign body sensation. Other symptoms include itching, excessive mucus secretion, inability to produce tears, a burning sensation, redness, pain, and difficulty moving the lids.

ASSESSMENT AND DIAGNOSTIC FINDINGS

- Slit-lamp examination shows an absent or interrupted tear meniscus at the lower lid margin, and the conjunctiva is thickened, edematous, hyperemic, and has lost its luster. A tear meniscus is the crescent-shaped edge of the tear film in the lower lid margin.
- Chronic dry eyes may result in chronic conjunctival and corneal irritation that can lead to corneal erosion, scarring, ulceration, thinning, or perforation that can seriously threaten vision. Secondary bacterial infection can occur.

MANAGEMENT

- Management of dry eye syndrome requires the complete cooperation of the patient with a regimen that needs to be followed at home for a long period, or complete relief of symptoms is unlikely.
- Instillation of artificial tears during the day
- An ointment at night is the usual regimen to hydrate and lubricate the eye through stimulating tears and preserving a moist ocular surface.
- Anti-inflammatory medications are also used e.g dexamethasone
- and moisture chambers (eg, moisture chamber spectacles, swim goggles) may provide additional relief.

Management of the dry eye syndrome also includes the concurrent treatment of infections, such as chronic blepharitis and acne rosacea, and treating the underlying systemic disease, such as Sjogren’s syndrome (an autoimmune disease).

In advanced cases of dry eye syndrome, surgical treatment that includes punctal occlusion, grafting procedures, and lateral tarsorrhaphy (ie, uniting the edges of the lids) are options. Punctal plugs are made of silicone material for the temporary or permanent occlusion of the puncta. This helps preserve the natural tears and prolongs the effects of artificial tears.

Short-term occlusion is performed by inserting punctal or silicone rods in all four puncta.

If tearing is induced, the upper plugs are removed, and the remaining lower plugs are removed in another week Permanent occlusion is performed only in severe cases among adults who do not develop tearing after partial occlusion and who have results on a repeated Schirmer’s test of 2 mm or less (filter paper is used to measure tear production.

COMPLICATIONS

- Damage of the eye
- Scarring of the cornea

PSEUDOTUMOUR

It is a poorly understood condition in which the orbit tissues become inflamed for no obvious reason. Its usually unilateral. There is no infection. Any part of the orbit can be affected. There is a history of a similar problem in the past.

CLINICAL FETURES

- Onset is rapid.
- Pain and inflammation.
- Restricted eye movement.

MANAGEMENT

Systemic steroid e.g. predinsolone 80mg given one week and then gradually reduced. Antibiotic cover
Biopsy may be taken if it recurs. And possibly chemotherapy and radiotherapy.

LACRIMAL TUMOUR

They are benign or malignant but benign tumours are more common.

CLINICAL FETURES

1. Onset is gradual.
2. There is a swelling in the upper lateral quadrant of the orbit.
3. There is proptosis.
4. The globe is displaced downwards and medially.

N/B: Malignant lacrimal tumours are often painful. They rapidly erode through the roof of the orbit into the brain.

MANAGEMENT

Surgery.

DYSTHYROID

It is a chronic inflammation of the extra-ocular muscles due to thyroid disorders e.g. thyrotoxicosis.

CLINICAL FETURES

Proptosis which appears exaggerated as the also have retraction of the upper lid.

Limited eye movement.

There is optic nerve compression due to the swelling of the muscles at the apex of the orbit.

MANAGEMENT

Treat the underlying thyroid problem.

Refer if there is double vision, exposure or optic nerve compression.

LYMPHOPMA

It affects the lower orbit.

CLINICAL FETURES

Rapidly increasing proptosis with a history of two weeks or less.

MANAGEMENT

Chemotherapy with cyclophosphamide but may relapse later.

Common is Burkitt's lymphoma mostly common tumour in children.

It arises in the maxilla and therefore

DISORDERS OF THE

LID

- Eyelids (L):
  - Protection:
    - Protects eye from foreign matter (dust, dirt, debris)
    - Protects against bright light that might damage the eye
  - Help spread tears over surface of eye- moist & comfort
- Eyelashes (L):
  - Filter out foreign matter
    - prevent it from getting into eye

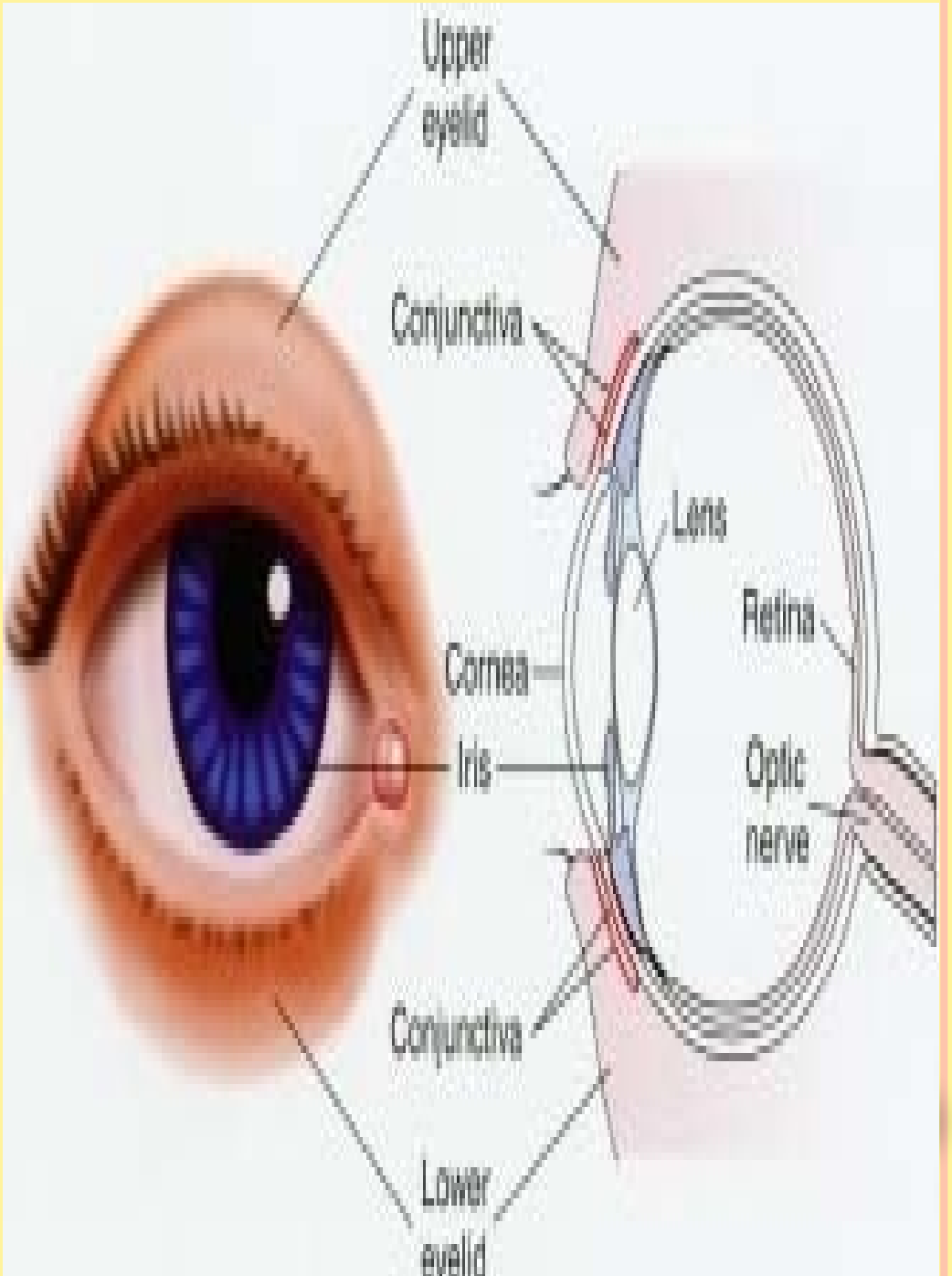

DISORDERS OF POSITION

These are as follows:

ENTROPION its a medical condition in which the eyelid (usually the lower lid) folds inward. It is very uncomfortable, as the eyelashes constantly rub against the cornea and irritate it. Entropion is usually caused by genetic factors. Lashes abrade the cornea causing:

- Pain.
- Watering.
- Photophobia
- Ulceration and scaring.

UPPER LID ENTROPION

Commonest type in Africa. It is caused by scaring and shortening of the posterior layer of the lid as a result of chronic trachoma. It is common in elderly, middle-aged patients and is rare in children.

LOWER LID ENTROPION

Commonest in developed world which is thought to be due to laxity of the ligaments that hold the lid in correct position. It occurs in elderly patients.

MANAGEMENT

This is by surgery which could be:

- Tarsoplate rotation.
- Mucous membrane graft.

N/B: Entropion may reoccur and therefore the patient is checked every year.

2. ECTROPION

- Its sagging and eversion of the lower lid and is usually bilateral. Its caused by relaxation of the orbicularis oculi muscle due to aging or following seventh nerve palsy.
- The lid margin turned out.
- It causes a watering eye and secondary infection with recurrent conjunctivitis. It is not cosmetically acceptable.

Severe ectropion, particularly of the upper lid, may lead to exposure and blindness.

PARALYTIC (Facial nerve palsy)

This is caused by the weakness in the orbicularis muscle.

Affects only the lower lid.

SENILE

1. This is due to the loss of tone in facial muscle, and the ligaments supporting the eyelid.
2. Affects only the lower lid, and occurs only in elderly patients.

others

- Congenital
- Scarring
- Allergic

MANAGEMENT

Surgical depending on the cause and severity of the ectropion.

Treatment of any exposure is urgent than the treatment of ectropion, therefore tetracycline eye ointment is applied to prevent drying of the eye.

SPECIFIC MANAGEMENT

CICATRICAL – full thickness skin grafting and lid reconstruction.

PARALYTIC – Tarsorrhaphy and horizontal lid tightening.

SENILE – horizontal lid tightening.

3. PTOSIS

Drooping of the upper eyelid causing inability to open the eye fully. It can be bilateral or unilateral. Patients often use forehead muscles and tilt the head in order to see. Children with unilateral ptosis may become amblyopic.

CAUSES

a. Congenital

This is as a result of developmental failure of the levator muscle of the lid**.**

B Acquired - Its in three categories

- **Mechanical factors** this is due to acute or chronic inflammatory edema or swelling, tumor**.** caused by senility, trauma and lid tumors.
- **Myogenic e.g. muscular dystrophy, myasthenia gravis** causes paralysis of the levator muscle.
- **Neurogenic (paralytic)** affect 3rd cranial nerve. Which supplies the levator muscle**.**

Clinical findings

- Smooth flat appearance on the affected and the tarsal fold caused by the levator muscle is absent. Its more noticeable in an upward gaze.
- Wrinkling of the forehead
- Amblyopia if one pupil is occluded.
- Ptosis in myasthenia gravis is gradual in onset and mostly evidence in the evening and improves overnight. Dx by injecting edrophonium which gives a dramatic response.

MANAGEMENT

1. Surgery- shortening the levator muscle.
2. Treat mysthenia gravis as indicated with neostigmine.
3. Patients can wear spectacles with a special frame which have a posteriorly attached wire clutch.

INFECTIONS OF THE LID.

1. STYE

A stye or hordeolum is a small, painful lump on the inside or outside of the eyelid. It is actually an abscess filled with pus usually caused by a staphylococcus bacteria eye infection.

Types of stye

An external stye is smaller and more superficial and affects the molls gland starts as a small spot next to an eyelash. It turns into a red, painful swelling that usually lasts several days before it bursts and then heals.

An internal stye (on the underside of the lid) it affects the meibomian gland. also causes a red, painful swelling, but its location prevents the familiar whitehead from appearing on the eyelid.

Treatment

- Warm compresses.
- Incision and drainage of the purulent material.

2. CHALAZION

- A **chalazion** also known as a **meibomian gland lipogranuloma.**
- Its a cyst in the eyelid that is caused by inflammation of a blocked meibomian gland, usually on the upper eyelid.
- It is a round firm swelling of the lid, not attached to the skin but firmly fixed to the tarsal plate.

- Chalazia differ from styes in that they are subacute and usually painless nodules. They may become acutely inflamed, but unlike a stye, chalazia usually sit inside the lid rather than on the lid margin. It is infection of the meibomian gland. Gland becomes blocked with mucous and swells.

Signs and symptoms

- Swelling on the eyelid
- Eyelid tenderness
- Sensitivity to light
- Increased tearing
- Heaviness of the eyelid

A chalazion or meibomian cyst can sometimes be mistaken for a stye.

Treatment

- Topical antibiotic eye drops or ointment (e.g. chloramphenicol are sometimes used for the initial acute infection.
- Healing can be facilitated by applying warm compress to the affected eye for approximately 15 minutes 4 times per day. This promotes drainage and healing by softening the hardened oil that is occluding the duct.
- If they continue to enlarge or fail to settle within a few months, smaller lesions may be injected with a corticosteroid, or larger ones may be surgically removed using local anesthesia
- Chalazia may recur, and they will usually be biopsied to rule out the possibility of a tumour.

b) SQUAMOUS CELL CARCINOMA

- Arise in the skin or conjunctiva. It is common in the upper lid. It affects the epithelial cells
- Often ulcerated but usually obvious mass.
- The tumour can metastasise.
- Skin cancers are rare to Africans, but conjunctival tumours are common.
- Risk of developing the tumour is related to exposure to sunlight.
- It is common to HIV patients.

MANAGEMENT

1. Invasive tumours may require enucleation.
2. Late presentation there risk of metastasis.

c) PAPILLOMA

Its any lesion on the eyelid that is of smooth, rounded or pendiculated elevation. Benign warts may arise on the skin or conjunctiva.

They are caused by the a virus and therefore virus particles may be shed into the conjunctiva, causing a chronic conjunctivitis.

MANAGEMENT

Remove the wart and cauterize the base.

4. TRAUMA

LID LACERATIONS.

- Injuries and lacerations of the lids are common results of accidents.
- They can be prevented by wearing safety belt.
- Injuries that does not involve the lid margin should be treated as other facial wounds, and can be sutured carefully in layers.

CONT'D.

- If the margin is involved, or if there tissue loss, the repair is more complicated since:
  - Inadequate repair may lead to scarring, with lid distortion, ectropion or even exposure.
  - Involvement of margin that affect the lateral ciliary should be repaired well to prevent scarring which will deform lid margin leading to ectropion or entropion.
  - Medial lacrimal, laceration to this part will damage the canaliculi resulting in a watery eye. The repair should be done by an ophthalmologist.

DISORDERS OF THE

CONJUCTIVA

DIAGRAM OF THE CONJUCTIVA

- Conjunctiva (Conj):
  - Thin, clear layer of skin
  - Covering of the front of eye
  - Covers the sclera and the inside of the eyelids
  - Function:
    - Keeps bacteria and foreign material from getting behind eye

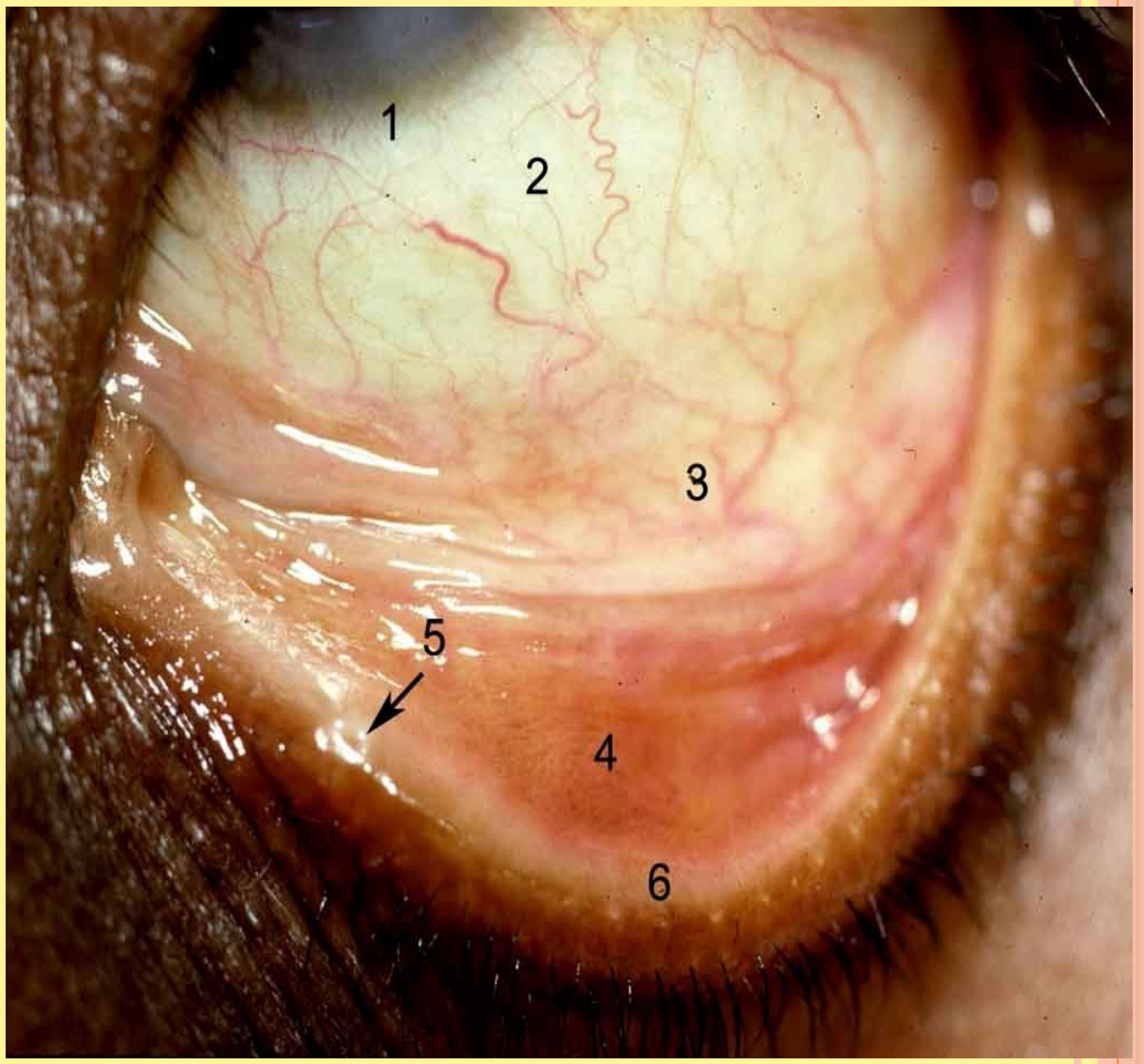

CONJUNCTIVITIS (Pink eye)

Conjunctivitis means inflammation of the conjunctiva. . It is characterized by a pink appearance (hence the common term *pink eye*) because of subconjunctival blood vessel hemorrhages.

It classified according to its cause

- ✓ Bacterial
- ✓ Allergic
- ✓ Chemical
- ✓ Viral
- ✓ Chlamydial

Clinical Manifestations

General symptoms include foreign body sensation, scratching or burning sensation, itching, and photophobia. Conjunctivitis may be unilateral or bilateral, but the infection usually starts in one eye and then spreads to the other eye by hand contact.

The four main clinical features important to evaluate are the type of discharge (ie, watery, mucoid, purulent, or mucopurulent).

MICROBIAL CONJUNCTIVITIS

Bacterial conjunctivitis can be acute or chronic. The acute type can develop into a chronic condition. Signs and symptoms can vary from mild to severe.

- The most common causative microorganisms are *Streptococcus pneumoniae, Haemophilus influenzae,* and *Staphylococcus aureus.*
- The conjunctiva is red, particularly in the lower fornix, where a purulent discharge may be visible.
- The condition is self-limiting, but can be treated with topical antibiotics, or regular face-washing.

- One rare but very serious form of bacterial conjunctivitis is caused by *Neisseria Gonorrhoeae* or *Gonococcus*.
- It usually affects very young babies, about 3-10 days old. They become infected from their mother's genital tract.
- The eyelids are very swollen, and there is a profuse purulent discharge. Within 24 hours both corneas can be totally destroyed and the child will be permanently blind.
- Gonococcal conjunctivitis can also occur in adults.
- Patients with a severe purulent conjunctivitis need an immediate swab and gram stain of their discharge, and should be treated with half-hourly antibiotic drops, and appropriate systemic treatment for gonorrhoea.

Ophthalmia neonatorum (conjunctivitis in young babies)

- ✓ Can be prevented by cleaning the eyes of babies at birth. Additional protection may be provided by giving a drop of an antibiotic or disinfectant (such as Silver Nitrate or Povidine Iodine) into each eye.

Allergic Conjunctivitis

- ✓ The most common form of allergic conjunctivitis is vernal catarrh.
- ✓ This is a chronic allergic condition that lasts 5-7 years before spontaneously resolving.
- ✓ Immunologic or allergic conjunctivitis is a hypersensitivity reaction as a part of allergic rhinitis (hay fever), or it can be an independent

Allergic Conjunctivitis contd…

There is extreme itching, epiphora (ie, excessive secretion of tears), injection, and usually severe photophobia. The string like mucoid discharge is usually associated with rubbing the eyes because of severe itching.

The patient usually has a history of an allergy to pollens and other environmental factors.

VERNAL CONJUNCTIVITIS

Vernal conjunctivitis is also known as seasonal conjunctivitis because it appears mostly during warm weather. There may be large formations of papillae that have a cobblestone appearance.

There are two types of vernal catarrh, limbal and tarsal.

- Limbal vernal catarrh have large papillae around the limbus.
- Tarsal vernal catarrh have papillae on the upper tarsal plate.

- Tarsal disease can cause corneal ulceration and scarring, but limbal disease is benign, although uncomfortable.
- It is more common in children and young adults. Most affected individuals have a history of asthma or eczema.
- Topical steroid drops make the eye feel much better, but the disease recurs when the drops are stopped.

- Long-term use of steroid drops may cause blindness. System steroids are more effective, but even more dangerous.
- Unless there is corneal ulceration, steroids should be avoided.
- The patient can be reassured that the disease will get better.
- Immediate symptomatic relief can be obtained by washing the eye with clean cold water.

Chemical Conjunctivitis

- This is caused by exposure to an irritant chemical, such as acids, tobacco smoke, snake venom, or the sap of certain trees, particularly *Euphorbia spp.*
- There is usually a history of the chemical entering the eye.
- The patient has a painful, watering, red eye.

Chemical Conjunctivitis

- If the exposure took place within the preceding few hours, it may be helpful to irrigate the conjunctival sac, but if it took place more than a few hours previously, irrigation is unlikely to be of benefit.
- Antibiotic drops should be given to prevent secondary infection.

Viral Conjunctivitis

Viral conjunctivitis can be acute and chronic. The discharge is watery, and follicles are prominent. The common causative organisms are adenovirus and herpes simplex virus. Conjunctivitis caused by adenovirus is highly contagious. The symptoms include extreme tearing, redness, and foreign body sensation that can involve one or both eyes.

The condition is usually preceded by symptoms of upper respiratory infection. Corneal involvement causes extreme photophobia. There is lid edema, ptosis, conjunctival **hyperemia** (i.e. dilation of the conjunctival blood vessels), watery discharge, follicles, and papillae. These signs and symptoms vary from mild to severe and may last for 2 weeks. Viral conjunctivitis, although self-limited, tends to last longer than bacterial conjunctivitis.

CONT,D.

There is no specific treatment, and the condition resolves spontaneously in 1-2 weeks.

Both types of viral conjunctivitis are very infectious, and great care must be taken to avoid transmitting the disease to other patients in your eye clinic, or to yourself.

TRACHOMA

Trachoma is a type of conjunctivitis also called chlamydial conjuctivitis which affects mainly the upper tarsal conjunctiva. It is bilateral chronic follicular conjunctivitis of childhood that leads to blindness during adulthood, if left untreated. The onset in children is usually insidious, but it can be acute or subacute in adults

TRACHOMA

The infection is caused by Chlamydia Trachomatis, a very small organism that is like both bacteria and viruses. It is similar to a virus because it cannot survive outside living cells; but is also like bacteria, because it can be killed by antibodies, and contains both DNA and RNA.

Epidemiology

The main reservoir of infection is young children. It has special affinity for the eyes and is usually bilateral. It is spread from one child to another by:

1) Direct contact
2) Flies
3) Indirect contact (shared cloth etc)

Others affected will be those in contact with the child e.g. the family members. Trachoma is commonest in hot dry areas with poor hygiene and an inadequate water supply.

The Life Cycle of Trachoma

INFECTING THE EYES

Flies carrying the micro-organism land on children's eyes, to feed on discharge.

FAMILY CONTACT

Women who take care of children also get the infection.

SPREADING OUT

Flies that breed in human feces spread the disease to others.

Dirty hands or face cloths also spread the disease.

HOW TRACHOMA BLINDS

Infections inflame and thicken the upper eyelid.

Scarred eyelids turn inward.

The lashes scratch the cornea, leading to blindness.

Sources: The Carter Center, International Trachoma Initiative

Al Granberg/The New York Times

Clinical Features

Where there is a high prevalence of trachoma, the patient may not complain of any symptoms, as Trachoma is regarded as “normal”. The patient may complain of a gritty, sticky eye, similar to other types of conjunctivitis. The signs of Trachoma are visible mainly on the upper tarsal conjunctiva. Trachoma infection is divided into 6 stages.

STAGES OF TRACHOMA

- TO No visible sign of Trachoma infection.
- TF Trachoma Follicles. Follicles are small (0.5-1mm), pale lumps in the conjunctiva. They are composed of white blood cells which have collected to fight the infection.

TRACHOMA STAGES…CONTD

- TI Trachoma Inflammation. The tarsal conjunctiva becomes red. As the small blood vessels dilate, they appear as papillae, which look like tiny red dots. This redness and swelling of the conjunctiva obscures the normal pattern of blood vessels.
- TS Trachoma Scarring. Repeated attacks of trachoma cause scarring of the conjunctiva. This appears as a slivery/white network under the conjunctiva. Later it gives the whole tarsal plate a thickened, distorted appearance.

TRACHOMA STAGES…CONTD

- TT Trachoma Trichiasis. Trichiasis means an eyelash touching the eye. This occurs because the scarred upper tarsal conjunctiva contracts, as a result of the scarring(like burns of the skin). This causes the upper lid margin to turn in – Entropion- and the lashes to touch the eye.
- CO Corneal Opacity. Corneal scar obscuring the pupil, due to Trachoma infection.

STAGES OF TRACHOMA

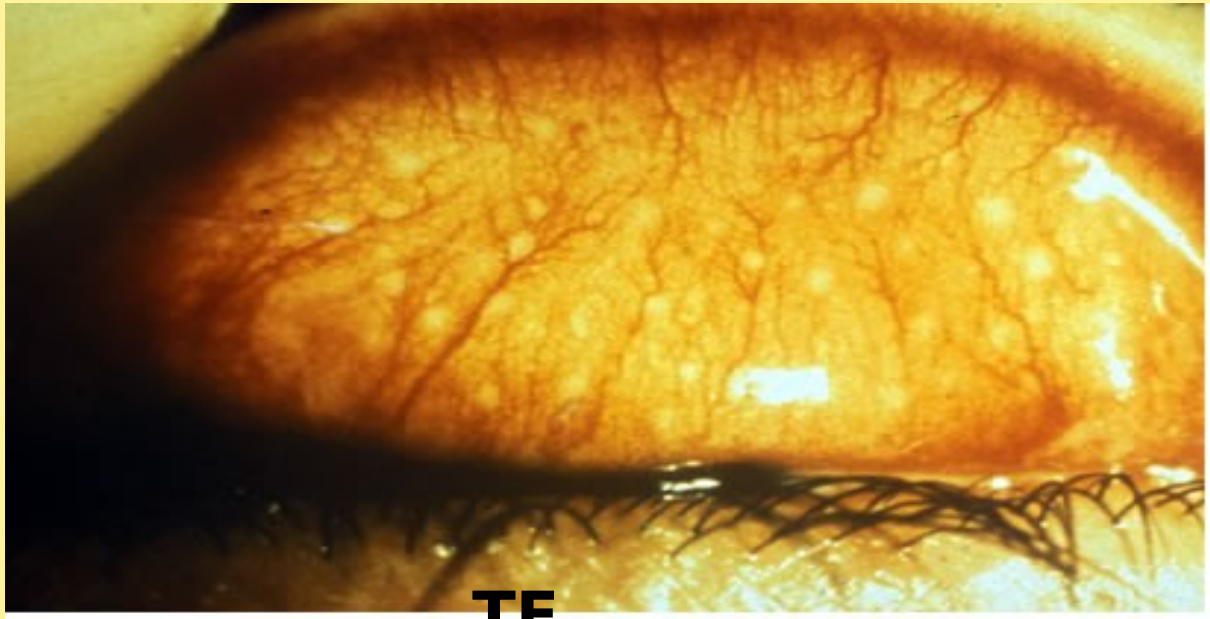

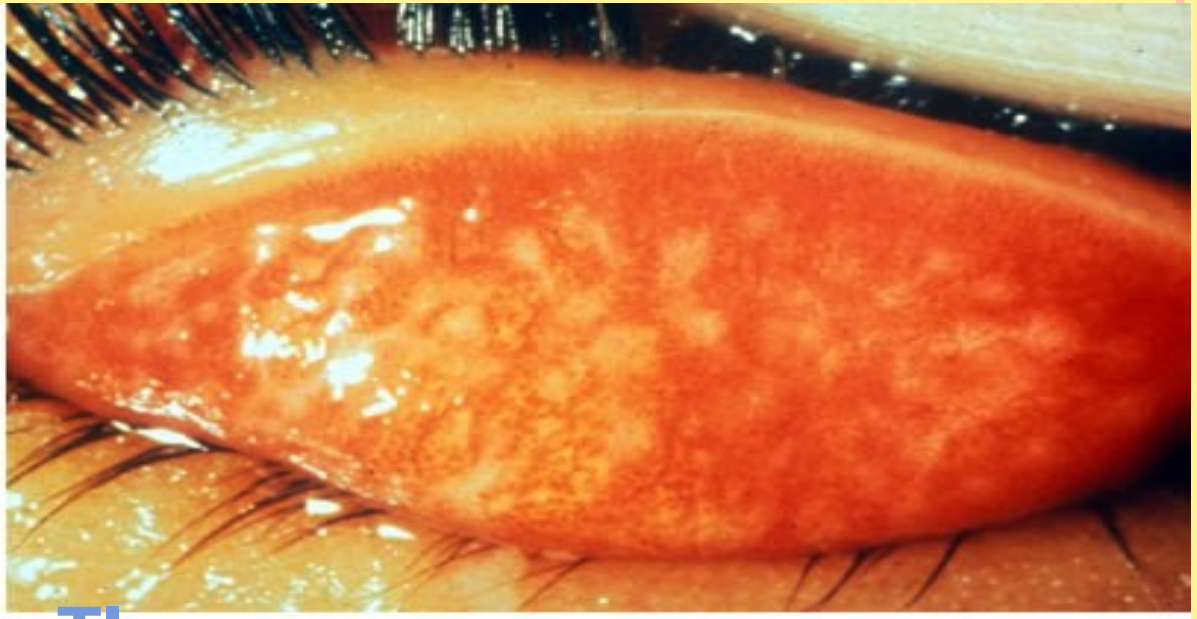

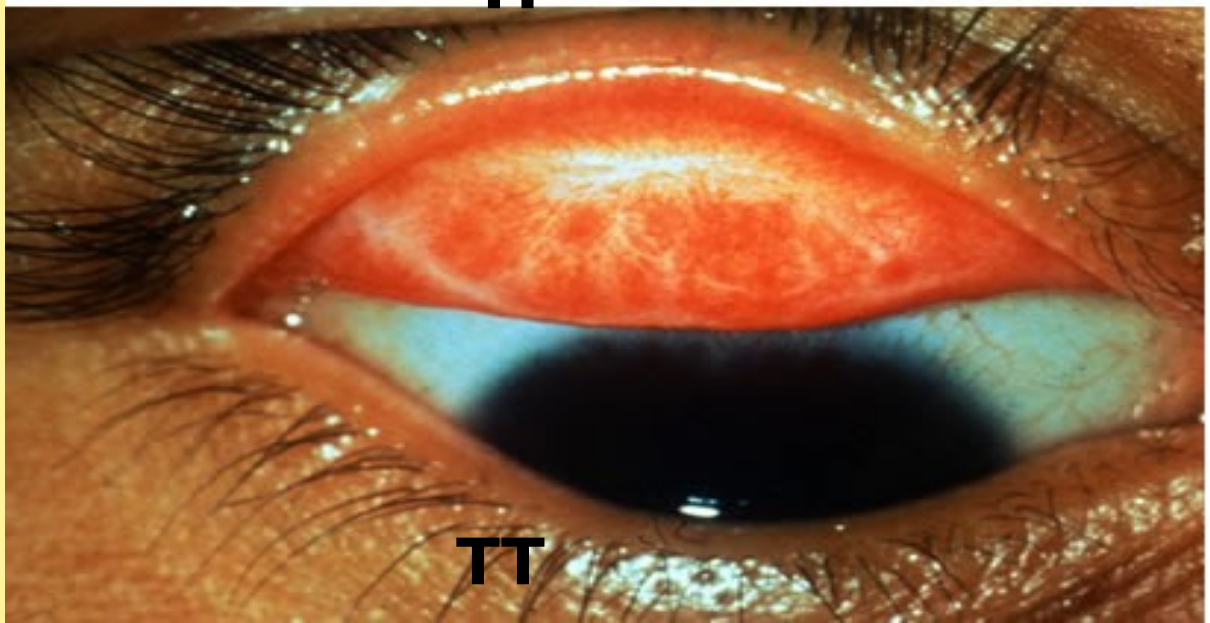

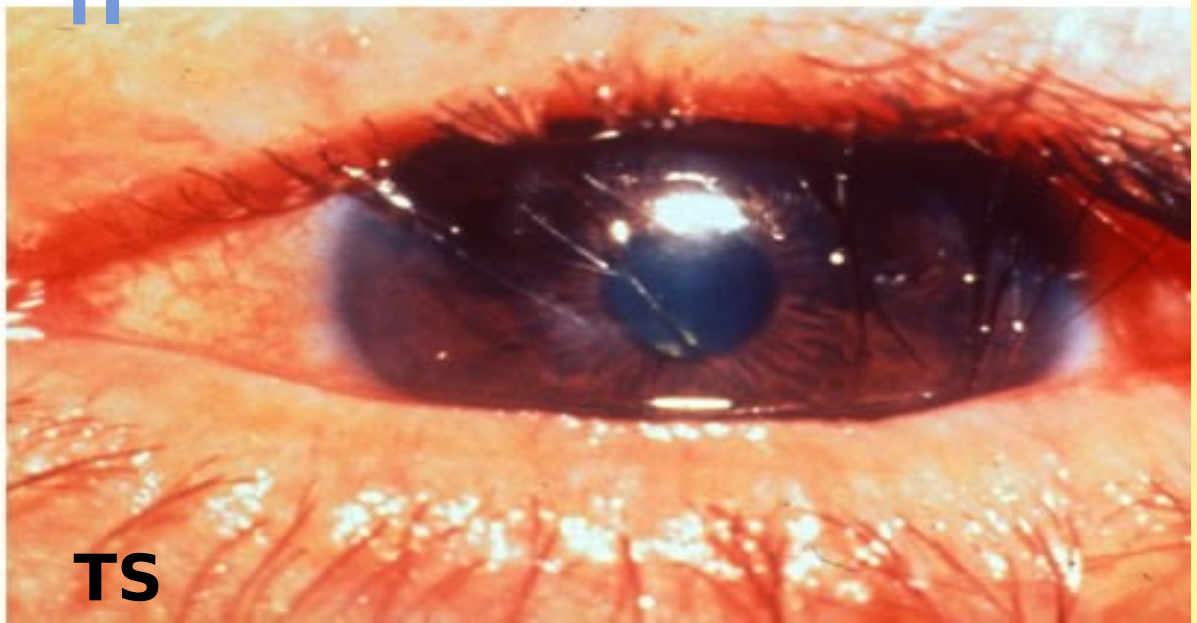

is severe inflammation there is increased likelihood
carring. When the inflammation is severe, this is
h larger numbers of infectious *Chlamydia*.
I should be given Oral Tetracyclin BD for 6 weeks to
of their Trachoma, and reduce the risk of scarring,
ortantly to eliminate the *Chlamydia* before another

s need lid surgery to correct the entropion

ess.

e easiest and quickest operation.

formed in the community by an ophthalmic

, it shortens an already contracted lid, and

r.

ne Grafting is more difficult and takes longer,

ter operation.

- Blinding Vs Non-Blinding Trachoma

Only 1% of patients with Trachoma go blind as a result of Trachoma. Blinding Trachoma is more likely to occur where there is a high prevalence of Trachoma, leading to repeated infections. Blindness is also more likely to occur if there is a combination of Trachoma and Bacterial Conjunctivitis. To prevent blinding Trachoma, it is not necessary to eliminate the disease completely. We need only reduce the prevalence.

Prevention of Blindness from Trachoma

1. Prevention of Trachoma: Trachoma transmission can be prevented by improving personal hygiene (e.g. face washing twice daily), and by improving environmental hygiene (measures to improve waste disposal, and reduce the fly population). However, prevention of Trachoma is a long term solution. Patients will continue to go blind for 20 years after the last case of Trachoma.

Treatment of Trachoma: Treatment of TI with Tetracycline. Speeds healing and lessens the risk of transmitting the infection to others. However, it is impossible to treat more than a small fraction of the cases of Trachoma in most areas where blinding Trachoma is a problem.

3. Treatment of Entropion: Entropion is curable. Once the entropion has been cured, there is no risk of blindness. If all patients with TT were identified and treated, that would have an immediate effect in reducing the incidence of blindness from Trachoma.

To prevent blindness from Trachoma, all three approaches should be used together. Methods will vary according to local circumstances.

Trachoma is the second commonest cause of blindness in the world, and **it is easily preventable.**

ASSIGNMENT

- Group one; Corneal disorders
- Group two; Corneal surgeries
- Group three; Pupil defects

CORNEAL DISORDERS

STRUCTURE OF THE SCLERA

- Sclera (S):
  - "White of the eye"
  - Tough, opaque tissue that extends around the eye
  - Surrounds the eye and gives the eye its shape
  - The sclera is attached to the extraocular muscles
- CORNEA; a transparent structure covering the iris

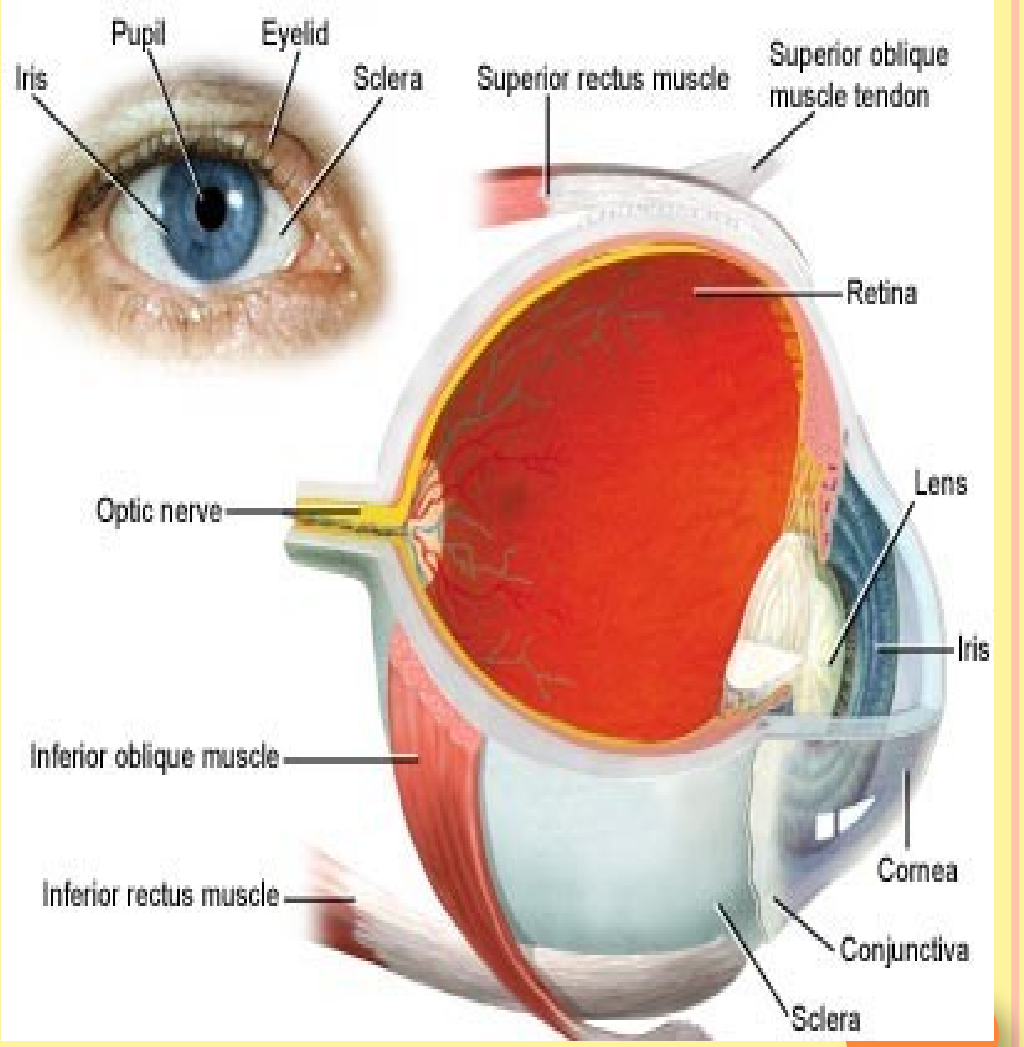

STRUCTURE OF THE CORNEA

- Cornea (K):
  - Clear layer at the front & center of eye
  - Located in front of the iris (colored part of eye)
  - Function:
    - Focus light as it enters eye
  - Avascular
    - Only organ that has no blood vessels

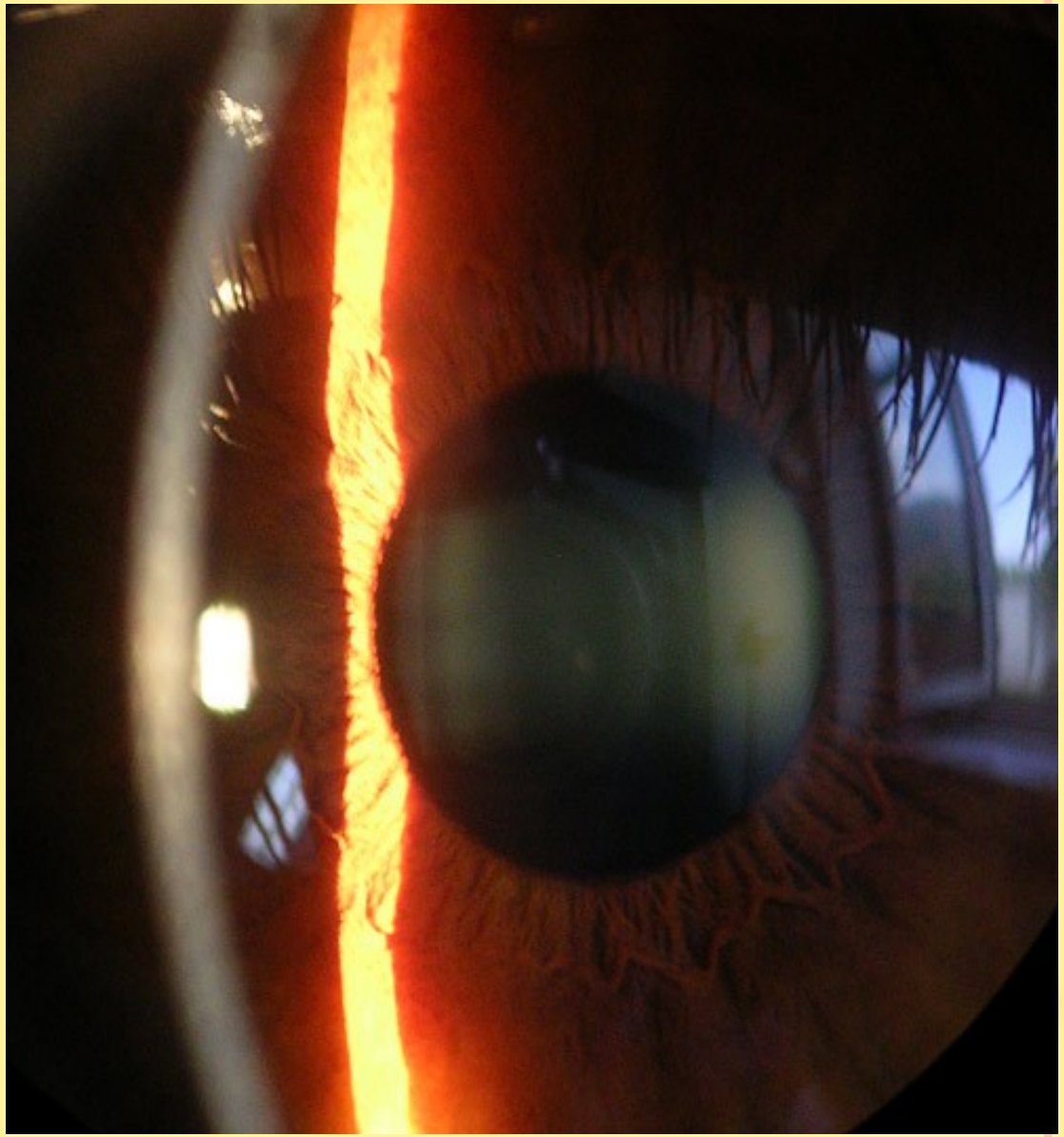

- Corneal ulcers
- Arcus senilis
- Lipid keratopathy
- Fusch’s dystrophy
- Kerato conjunctivitis sisca (dry eye)

CORNEAL ULCERS

- **Definition:** its also called ulcerative keratitis which is an inflammatory or an infective condition of the cornea involving disruption of its epithelial layer with the involvement of the corneal stroma.
- Corneal healing
- It heals by two methods;
- migration of surrounding epithelial cells followed by mitosis.
- Introduction of blood vessels from the conjuctiva.

- Scarring cannot be cured. However, corneal scars are the result of corneal ulcers and can be prevented by proper treatment of the ulcer
- Corneal ulcer affecting epithelium only will heal rapidly without sequelae.
- Ulcer involving stroma will heal with scarring and vascularisation
- As the ulcer deepens to nearly full thickness, the endothelial layer of the cornea bulges out as a descemetocoele.

SIGNS AND SYMPTOMS

1. All corneal ulcers are very painful.
2. Photophobia
3. Watering of the eyes.
4. Mild or severe eye discharge
5. Reduced vision

Causes

There are many different causes of corneal ulcer:

1. Traumatic corneal abrasion/Entropion
2. Bacterial corneal ulcer
3. Herpes Simplex
4. Vitamin A deficiency
5. Traditional Eye Medicine/Other chemicals
6. Exposure
7. Corneal anaesthesia
8. Others – use of predinsolone
9. Burns

DIAGNOSIS

Definitive diagnosis is made with fluorescein, which stains exposed stroma a bright green.

N/B: IT IS ESSENTIAL TO STAIN RED EYES WITH FLOURESCEIN

Having diagnosed a corneal ulcer, the cause should be determined, in order to start specific treatment as quickly as possible. However, ALL corneal ulcers should be treated with Atropine and most should be given topical antibiotic. If there is doubt, give Atropine and antibiotic only. Remember that appropriate treatment will prevent blindness but inappropriate treatment will cause it.

SPECIFIC DIAGNOSIS AND TREATMENT TRAUMATIC ABRASION

- There is usually a history of trauma, or there is obvious trichiasis.
- Treatment is topical antibiotic and atropine. If the abrasion is not infected, the eye should be padded for 24 hours for 3/7

i. BACTERIAL CORNEAL ULCER

COMMONEST CAUSES

1. Staph Aureus.
2. Pneumococcus.
3. Pseudomonas.

SIGNS AND SYMPTOMS

- Very red eye.
- Purulent discharge.
- Grey corneal ulcer.
- Hypopyon.

Treatment:

1. Dilate pupil intensively.
2. Hourly antibiotic E.G. Genta , Chlorolamhenical
3. Sub-Conjunctival Antibiotic – Daily every day if there is a hypopyon.
4. Best is Gentamycin 40mg. Alternatives are Chloramphenicol or Penicillin and Streptomycin.
5. Gentamycin drops – 8mg/ml hourly and 1m subconjuctival injections 40mg daily.

b. FUNGAL KERATITIS; its caused by fusarium which came as an outbreak among contact lens wearers who used a certain dye of contact lens solution.

c. ACANTHAMOEBA KERATITIS; caused by parasites which can enter the eye called acanthamoeba that can result in very serious eye infection which can result in permanent scarring of the cornea and vision loss. They are commonly found in tap water, swimming pools, hot tubs and other water sources. Contact lens wearer who fail to remove their lenses before swimming increases their risk for a corneal ulcer.

d. HERPES SIMPLEX INFECTION

Its caused by herpes simplex virus.

PATHOPHYSIOLOGY

Herpes virus is dormant (sleeping) in the trigeminal nerve and comes out when the body's defences are weakened e.g. by fever (esp. Malaria), malnutrition, etc. Spreads down the Nerve Ophthalmic division and infects corneal epithelium. Ulcers take two forms:

- Dendritic
- Geographical/Amoeboid

SIGNS AND SYMPTOMS

- Redness of the eye.
- Pain
- Photohobia
- Watering of the eye
- Blurred vision.
- Blisterly skin rash around the eyelids

TREATMENT

1. Geographical ulcers may be accompanied by a dense stromal infiltrate, and intense corneal vascularisation. They can only be treated with antivirals. E.g. acyclovir
2. A dendritic ulcer may be treated by removing infected cells with STERILE cotton wool. The residual ulcer heals in a few days. If the ulcer recurs, remove infected cells again and give antiviral e.g. until healed.

N/B: If tropical steroids are given to a patient with dendritic ulcer, the ulcer will enlarge and perforate.

Antiviral drugs do not kill the virus but stops it from multiplying further until the infection clears.

E. TRADITIONAL EYE MEDICINE/CHEMICAL BURNS

TEM damage the eye by:

- Infection from unsterile preparation
- Delay in presenting to eye clinic
- Chemicals e.g. acid, alkali
- Physical e.g. heat, Foreign Body

As long as eye clinics are remote from patients, people will continue to use TEM. Aim to prevent by making eye care more accessible and dialogue with Traditional Healers.

TREATMENT:

- Refer as for bacterial ulcers
- The most dangerous chemicals in the eye are alkalis e.g., caustic soda or lime. These injuries should be prevented by use of goggles and immediate first aid, consisting of copious irrigation of eye with sterile saline or water.
- If the ulcer appears severe – admit. All cases should receive antibiotic and atropine.

f. EXPOSURE

1. Exposure occurs when the eyelids do not cover the cornea
2. Paralysis – VII N Palsy, coma and debility(due to Facial Nerve Leprosy)
3. Mechanical – Proptosis, loss of lid.

MANAGEMENT

4. Antibiotic ointment is used to reduce drying.
5. The underlying cause must be treated e.g., by tarsorrhaphy, orbital surgery.

G. VITAMIN A DEFICIENCY

A common cause of corneal scarring and blindness in developing countries.Vitamin A deficiency not only causes blindness, but also kills many thousands of young children every year.

FUNCTIONS VITAMIN A

1. To make the light sensitive pigment in the rod cells of the retina.
2. In the growth and maintenance of mucous epithelium
3. In the body’s defenses against disease.

CAUSES OF VIT A DEFICIENCY

MALNUTRITION - vitamin A deficiency may occur gradually as a result of diet low in vitamin A.

Protein deficiency prevents synthesis of protein used to transport Vit A in the blood leading to clinical Vitamin deficiency.

MEASLES - Because the body's stores of Vitamin A are suddenly used up as the epithelium of skin, gut, lungs, mouth and eyes is replaced, in this situation, Vitamin a deficiency is sudden and severe.

MALABSORPTION -Malabsorption is common following diarrhea, or as a result of parasitic infection, and leads to Vit A deficiency despite an adequate dietary intake.

CLINICAL FEATURES

Night Blindness – not seeing at night as a result of inadequate levels of retinol, the light sensitive pigment in photoreceptor cells.

Fundus Lesions - Rarely seen, these are white dots in retina.

Bitot's Spot - Collection of cells and mucus which appears as patch of foam/froth just outside limbus. May persist despite adequate treatment.

Scarred Cornea - The result of vitamin A deficiency.

Conjunctional Xerosis (Xerosis =Dryness) Conjunctiva appears dull and wrinkled

CLINICAL FEATURES CONT,D.

Corneal Xerosis- Cornea appears dull and dry

Corneal Ulcer - Sharply demarcated ulcer, usually affecting lower half of cornea. May perforate, becoming plugged with iris. Ulcer heals to leave dense white scar, possibly with anterior Synechiae resulting in an *adherent leucoma*.

Corneal Necrosis (Keratomalacia). Entire cornea becomes soft and necrotic ocular contents are lost. Eye becomes phthisical, or if healing occurs, Anterior staphyloma is formed.

TREATMENT AND PREVENTION

Treat according to the cause

1. Vit A 200,000 i.u orally on days 1,3 and 7 (100,000 i.u. in children <1yr old)
2. Patients at risk of Vitamin A deficiency, but without overt signs of clinical Vit A deficiency, (e.g., Children with marasmus, measles, severe diarrhea) must be given Vit A 200,000i.u orally. (100,000i.u in children <1yr old)
3. Since most cases occur following measles, prevention of measles and other severe childhood illnesses by immunization will reduce the number of children suffering from Vit A deficiency.

Foods rich in Vit A are relatively cheap and plentiful. They include:

1. Green leafy vegetables
2. Paw paw
3. Mangoes
4. Eggs
5. Liver and
6. Red palm oil.

NOTE:

- Mothers should be encouraged to introduce Vit A rich foods before the child is completely weaned.
- If possible the whole community should be involved in the prevention of Vitamin A deficiency.

CONT,D.

- Agricultural experts may be able to give advice on how to increase the dietary supply of vit A. Teachers and others can participate in dietary education.
- In Kenya, blindness from Vit A deficiency should be totally preventable.
- **Vit. A deficiency will not be prevented by an Ophthalmologist in an eye clinic, but by the MCH nurses in the villages.**

CORNEAL DYSTROPHIES; (EPITHELIAL AND STROMAL)

Corneal dystrophies are inherited as autosomal dominant traits and manifest when the person is about 20 years of age. They are characterized by deposits in the corneal layers. Decreased vision is caused by the irregular corneal surface and corneal deposits. Corneal endothelial decompensation leads to corneal edema and blurring of vision.

Symptomatic treatments, such as hypertonic drops or ointment (5% sodium chloride), may reduce epithelial edema; lowering the IOP also reduces stromal edema.

Penetrating keratoplasty has a high success rate in advanced cases. For diffuse bullous keratopathy, amniotic membrane transplantation may become the procedure of choice for patients with limited visual potential.

KERATOCONUS

Keratoconus is a condition characterized by a conical protuberance of the cornea with progressive thinning on protrusion and irregular astigmatism. The hereditary condition has a higher incidence among women. Onset occurs at puberty; the condition may progress for more than 20 years and is bilateral. Corneal scarring occurs in severe cases. Blurred vision is a prominent symptom

Rigid, gas-permeable contact lenses correct irregular astigmatism and improve vision. Advances in contact lens design have reduced the need for surgery. Penetrating keratoplasty is indicated when contact lens correction is no longer effective.

CORNEAL SURGERIES

Phototherapeutic Keratectomy

PTK is a laser procedure that is used to treat diseased corneal tissue by removing or reducing corneal opacities and smoothing the anterior corneal surface to improve functional vision.

Its contraindicated in patients with active herpetic keratitis because the ultraviolet rays may reactivate latent virus.

Side Effects

- Induced hyperopia
- stromal haze.

Complications

- Delayed re-epithelialization (particularly in patients with diabetes)
- Bacterial keratitis.

Postoperative management

- Oral analgesics for eye pain.
- Re-epithelialization is promoted with a pressure patch or therapeutic soft contact lens.
- Antibiotic and corticosteroid ointment and NSAIDs are prescribed postoperatively.
- Follow-up examinations are required for up to 2 years

KERATOPLASTY

Keratoplasty (ie, corneal transplantation or corneal grafting) involves replacing abnormal host tissue with a healthy donor corneal tissue.

Indications

- Keratoconus,
- Corneal dystrophy
- Corneal scarring from herpes simplex keratitis
- Chemical burns.

Nursing Management

- Reinforcing the surgeon’s recommendations and instructions regarding visual rehabilitation and visual improvement.
- Assessing the patient’s support system and his or her ability to comply with long term follow-up,
- Selective suture removal and ongoing evaluation of the graft site and visual acuity.
- Initiating appropriate referral to community services when indicated.

- Teaching the patient to identify signs and symptoms of graft failure. E.g blurred vision, discomfort, tearing, or redness of the eye. Patients must contact the ophthalmologist as soon as symptoms occur. Treatment of graft rejection is prompt administration of hourly topical corticosteroids. Systemic immunosuppressive agents may be necessary for severe, resistant cases.

Radial Keratotomy

Radial keratotomy (RK) is indicated for low myopia. The procedure involves making four to eight, deep, radial incisions in the paracentral and peripheral cornea with a metal or diamond blade. The corneal contour then becomes flatter.

common side effects

Glare, photosensitivity, fluctuations of vision during the day and occasional diplopia

Laser Vision Correction Photorefractive Keratectomy

Its a procedure used to treat myopia and hyperopia with or without astigmatism. The excimer laser is applied directly to the cornea according to carefully calculated measurements. For myopia, the relative curvature is decreased; for hyperopia, the relative curvature is increased. A bandage contact lens is placed over the cornea to promote epithelial healing and reduce pain similar to that of severe corneal abrasion.

Laser-Assisted In Situ Keratomileusis (LASIK)

LASIK involves flattening the anterior curvature of the cornea by removing a stromal lamella or layer. The surgeon creates a corneal flap with a microkeratome, which is an automatic corneal shaper similar to a carpenter’s plane. The surgeon retracts a flap of corneal tissue less than one third of the thickness of a human hair to access the corneal stroma and

then uses the excimer laser on the stromal bed to reshape the cornea according to calculated measurements . The corneal flap, a naturally adhering bandage, is rolled back and repositioned. LASIK also appears to be an effective, predictable, stable, and safe procedure for correcting residual myopia after cataract surgery.

LASIK causes less postoperative discomfort, has fewer side effects, and is safer than PRK. The patient has no corneal haze and requires less postoperative care. With LASIK, however, the cornea has been invaded at a deeper level, and any complications are more significant than those that can occur with PRK.

DISORDERS OF THE

PUPIL

STRUCTURE OF THE PUPIL

- Pupil (P):
  - Central opening of iris
- Iris (I):
  - Ring shaped tissue
  - Colored part of eye
  - Controls the amount of light that enters the eye
- Two muscle fibers:
  - Contraction
    - Constricts pupil in bright light
  - Dilation
    - Dilates pupil in dark

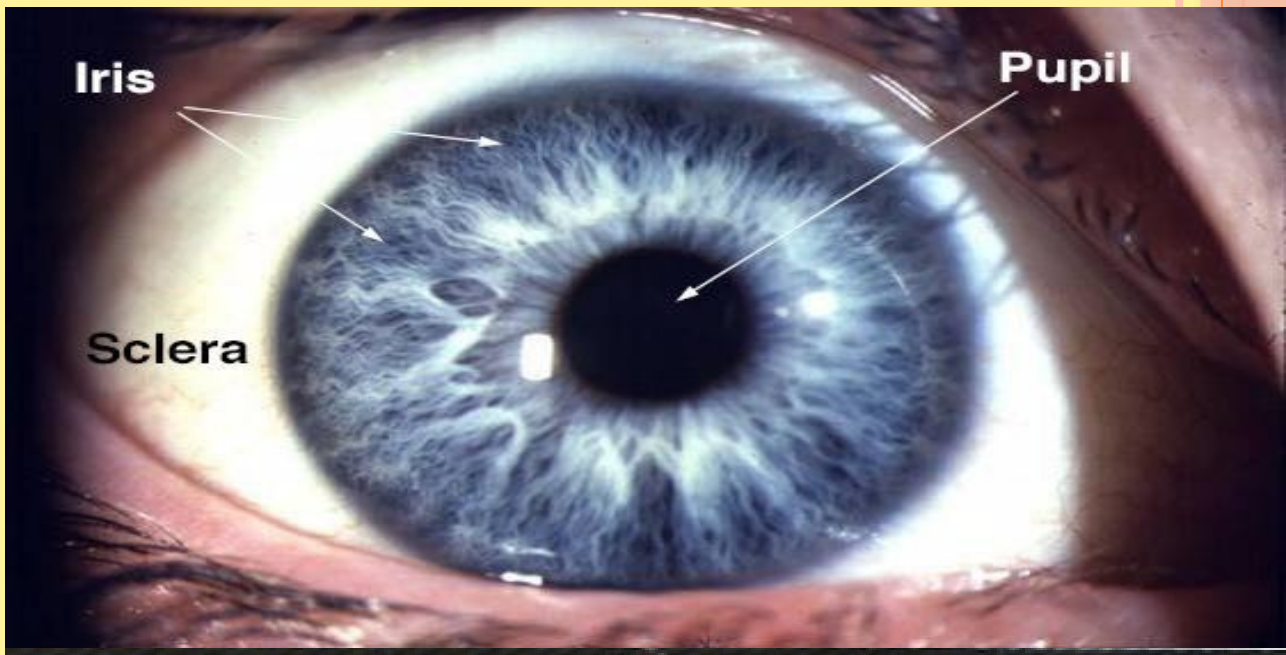

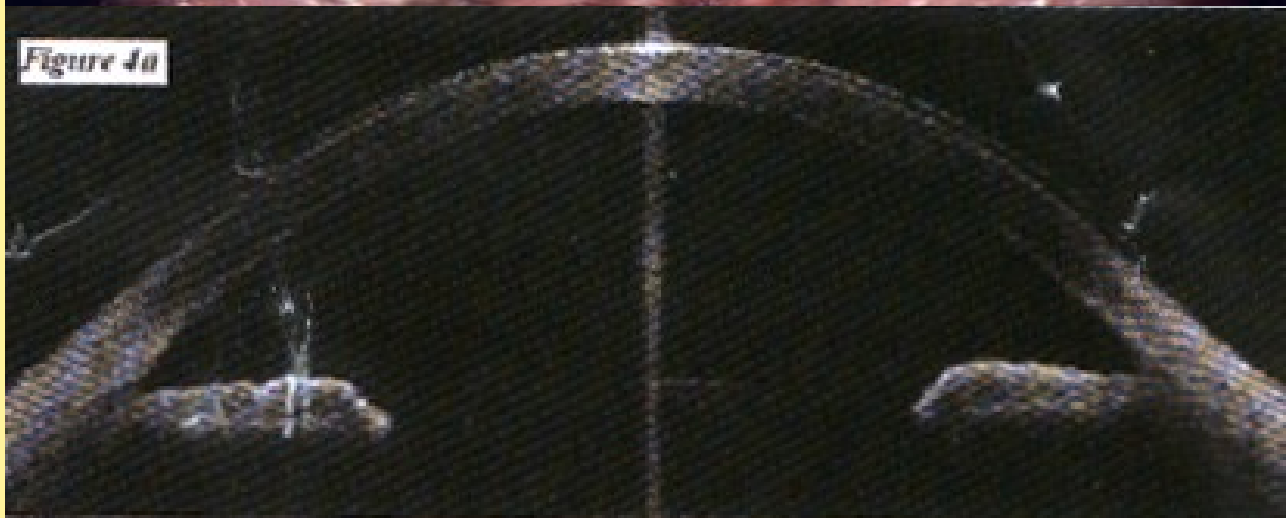

OVERVIEW

- There are two nerves involved in pupillary responses:
- **Optic Nerve (II) –** this is the **afferent nerve –** it detects the light, and sends this signal to the brain. **HOWEVER –** a defect in the afferent nerve does not necessarily have to be in the optic nerve itself, it could be at the optic chiasm (likely to be bilateral), or in the optic tract. **Anywhere along the afferent pathway.**

- **Occulomotor nerve (III) –** this is the **efferent nerve –** when the brain receives a signal about strong light from **EITHER EYE –** it will send a signal down **both occulomotor nerves,** telling the pupil to constrict

PUPIL

The pupil is the opening in the iris through which light enters the eye.

The pupil constricts in response to

1) Increase in light
2) Looking at a near object

Pupil light reflex depends on intact:-

3) Retina
4) Optic nerve
5) Oculomotor nerve
6) Iris sphincter

Afferent is the sensory part of the reflex, carrying information to the brain, from the retina

Efferent is the motor part of the reflex carrying information from the brain to the iris sphincter muscle.

A defect of the retina or optic nerve will cause an afferent pupil defect.

A defect of the oculomotor nerve or iris sphincter muscle will cause an efferent pupil defect

AFFERENT PUPIL DEFECT

- It’s a medical sign observed during the swinging flashlight test where the patients pupil constrict less therefore appearing to dilate when a bright light is swung from the unaffected eye to the affected eye.
- It indicates a decreased pupillary response to light in the affected eye.
- In this test equal constriction of both pupil will be experienced regardless of which eye the light is directed to. In this condition light directed in the affected eye will cause only mild constriction of both pupils while light on the unaffected eye will cause a normal constriction.

1) If the defect is unilateral

If the defect is unilateral afferent defect the pupil light reflex from the other eye will be intact so that if you shine a light in the normal eye both the normal and abnormal pupils will constrict. On the other hand, if you shine the light in the abnormal eye, neither pupil will constrict. This is the basis of the swinging torch test.

2) If the defect is bilateral

In an affferent pupil defect, only the light reflex is affected. This means that even if neither eye can perceive light, the pupils will still constrict if the patient looks at his own finger from a short distance, as the accommodation reflex is preserved.

EFFERENT PATHWAY

- Action potential passes to right and left Edinger-westphal nuclei of CN III (oculomotor nerve) via interneuron's (black lines with arrows)
- Then to the right and left ciliary ganglions via oculomotor nerve
- ***Constriction of***
  - Pupil being illuminated (A) = direct reflex
  - Contra lateral pupil (B) = consensual reflex

EFFERENT PUPIL DEFECT

This is where there is neither a direct or a consensual response to light or accommodation. It may be caused by an oculomotor nerve palsy.

The pupil remains dilated regardless of where the light is shining

- Anisocoria
- Argyl Robertson uils common in neurosyhilis and dm neuroathy
- Bene dilitasm affects otic nerve
- Marcus gunn uil
- Hius
- Light near dissociation
- Leukocaria
- Aniridia

RELATIVE AFFERENT PUPILLARY DEFECT (RAPD/MARCUS GUNNPUPIL

Marked – shining the light in the **affected eye** will result in **no constriction of either pupil. E.g –** a RAPD in the left eye – shining the light in the left eye will result in no constriction of either pupil. Shining the light in the right eye will result in constriction of both pupils.

- This is due to **damage to the left afferent pathway**
- **Bilateral presentation – neither pupil will contract in response to light in either eye.**
- **Mild –** shining the light in the **affected eye** will result in a slow **constriction of both pupils,** but then a gradual **dilation of both pupils.**
- the most common cause is severe retinal disease or a lesion of the optic nerve, optic neuritis, glaucoma, ischaemic optic neuropathy, traumatic optic nerve neuropathy, infections in the optic nerve, radiation to optic nerve, surgery

CLASSIFICATION

- Mild- there ois presence of weak pupillary constriction followed by puppilary dilation when light is directed to the affected eye.
- Moderate- abcense of initial constriction followed by dilation of the affected eye.
- Severe – immediate dilation when light is shone on the affected eye.

DIAGNOSIS

- Swinging flash light test
- MRI

TREATMENT

Depending with the cause

- Steroids e.g. prednisolone
- Antibiotic theraphy; eye drops
- Miotic eye drops especially in cases of glaucoma to reduce pressure e.g. pilocarpine
- Interferones for patients with multiple screlosis induced to promote myelination.
- Surgery if condition does not improve

HORNER'S SYNDROME

- The responses are actually **NORMAL –** however, on the affected side:
- There is ptosis
- The pupil is naturally quite constricted. It will still respond *relatively* to light (ie. It will constrict further, and will dilate somewhat in the dark), but its generally 'resting' state is constricted to a greater degree than a normal pupil.

Signs and symptoms

- Persistently small pupil
- Anisocoria- noticeable difference of pupil size betwee the two eyes.
- Ptosis- drooping of the upper eyelid
- Delayed opening of the affected pupil in dim light
- Upside down ptosis
- Decreased sweating on the affected side of the face
- Lighter eyelids colour in the affected eye
- Others; dizinness, neck pain

HORNER'S SYNDROME

Cause

- Tumor of the optic nerve
- Trauma
- Cyst of the optic nerve
- Damage to jugular vein
- Damage to certain pathway in the sympathetic nervous system

<u>Diagnosis</u>

CT scan

MRI

X-ray

<u>Treatment</u>

Treat the underlying cause

THIRD NERVE (EFFERENT) PALSY

- The affected side will have:
  - An eye that points **down and out**
  - A dilated pupil that **does not respond to light in either eye.**

However! – as the afferent is still functioning normally:

- The contralateral eye will respond to light *in the affect eye.* And the contralateral eye will respond normally to its own light.

DISORDERS OF THE LENS

ANATOMY AND PHYSIOLOGY REVIEW

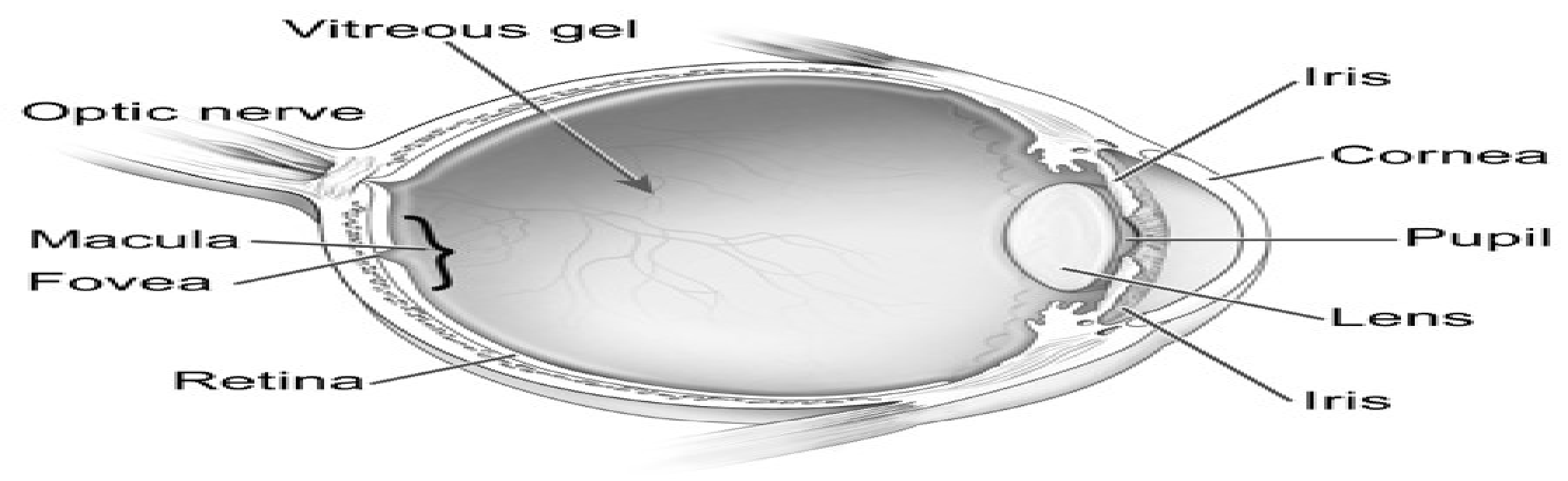

The lens is composed of a central nucleus, surrounded by the cortex. The lens is attached to the ciliary body, just behind the iris. As the ciliary muscle contracts, the zonular fibres relax, allowing the lens to become fatter, and changing the focal point of the eye

THE LENS cont….

- When fully developed it is transparent biconvex and totally a vascular. It gets its nutrition from the aqueous humour in which it is bathed.
- It is enclosed within a capsule and is suspended by means of suspensory ligament attached to ciliary body .

THE LENS CONT….

- The function of the lens is to refract (or bend) the rays of light entering the eye and so bring them to a focus on the retina.
- The lens can alter in convexity and so can focus object at various distances.

CATARACT

Its a Lens is Opacity or cloudiness

Types/Causes

- Congenital: Through maternal illness e.g. German measles
- Trauma: injury to lens capsule, dislocation following glaucoma operation, heat, irradiation etc
- Secondary to ocular diseases or uveitis.
- Systematic diseases e.g. Diabetes mellitus
- Senile cataract (most common):- degenerative changes

CLINICAL FEATURES

- Gradual painless loss of sight.
- Opacity of the lens.

DEGREES OF OPACITY

- Immature cataract- only part of the capsule is opaque
- Mature - whole of the Lens is opaque

MANAGEMENT = SURGERY

1. **Congenital Cataract**

In children the lens is soft material within capsule.

Needling And Aspiration is done:

- Here the needle is introduced into the cortex and then withdrawn. The material is absorbed by aqueous humour. Alternatively the whole content of the cortex is aspirated with a syringe.
- Then Lens inserted Intra-capsula.
- Subconjunctival –Gentamycin and Dexamethazone

OR

The patient will be able to see with the help of lens glasses .

2. ADULT CATARACT

Any of the following may be done:-

A:- **Intra Capsular Extraction**

Here the whole lens is removed, cortex and capsule. The suspensory ligament holding the lens in position behind the pupil is ruptured and the lens is delivered complete with its capsule. Removal of the whole lens. Vision corrected by thick glasses / contact lenses

B:- **EXTRA – CAPSULAR EXTRACTION**

- Removal of part of the lens material then put an artificial (intraocular) lens implant

Here the posterior capsule of the lens is left behind. The anterior capsule is ruptured and lens expressed through the pupil and out

- An intra-ocular lens then fixed.
- Subconjunctival –Gentamycin and Dexamethazone.

Following either of the procedures. Lens fitted. Or the patient can use lens glasses

PHACOEMULSIFICATION

- Carried out through a small (2.5mm to 3mm), self-sealing incision.
- A high frequency ultra-sonic probe emulsifies or breaks the nucleus into small fragments and sucks the microscopic particles of the nucleus material out of the eye.
- A specially designed foldable intra-ocular lens (IOL) is then inserted, providing a permanent and safe replacement for the natural lens.
- This surgery is performed under local anesthesia.

PRE OPERATIVE MANAGEMENT FOR CATARACT EXTRACTION

1. Investigations

- Pus swab from conjunctiva to rule out presence of pathological organisms so as to treat appropriately

INVESTIGATION

- Exclude any systematic diseases e.g. hypertension
- Chest X ray to rule out chronic bronchitis any persistent cough after operation will tend to make the incision gape.
- Rule out e.g. Diabetes mellitus

PRE-OP.

2. Instructions to patient

- Explain what will be done what is expected of him after operation e.g. having his eyes padded, position in bed, being fed, being in bed etc being quiet after operation etc
- Consent

PRE. OP----

3. **Personal Hygiene**

4. **Diet:** Light, balanced with extra proteins and vitamins, A, B & C

ON EVENING BEFORE SURGERY

- Cut eye lashes and area around the eye shaved with sterile blade.
- Light super.
- Starve 6 hours before operation.

DAY OF SURGERY

- If under L.A early light breakfast
- Vital signs and blood pressure
- Urinalysis
- Bath

- Instil mydriatic eye drops as prescribed atropine ¼ hourly starting 2 hours
- Reassure patient
- Dress in theatre gown etc
- Give any pre-medication prescribed e.g Atropine

GENERAL GOALS

To prevent:-

- Infections
- Increased intra ocular pressure
- Stress on suture line
- Haemorrhage to anterior chamber

TO ACHIEVE GOALS, THE FOLLOWING MUST BE DONE

- Lie propped up on back with 1 – 2 pillows and to be fed 3 – 4days
- Complete bed rest 5 – 7 days depending on condition.
- Avoid food for 1st 2 hours

TO ACHIEVE GOALS.. CONT….

- Examine eye before starting to clean. Note any abnormality lid suture if any removed usually 1st dressing done by the doctor (patient can go home 24 hours following surgery).
- Clean gently with warm N/saline. Done daily until the doctor terminates
- Avoid strong light.

TO ACHIEVE GOALS.. CONT….

- Instillation of prescribed medication e.g. antibiotic ointment and steroid.
- After 7th day eye padded at night and patient uses dark glasses during the day.
- Avoid constipation e.g. give liquid paraffin as prescribed

TO ACHIEVE GOALS.. CONT….

- Exercises started on 3rd day to avoid complications.
- Personal hygiene.
- Patient to be followed in eye clinic (or the other eye operated)

REFRACTIVE ERRORS

STRUCTURE OF THE RETINA

Retina:

- Acts like the film in a camera to create an image
- Consists of a specialized layer of cells
- Converts light signals into nerve signal then send these signals to the optic nerve
  - Optic nerve carries the signals to the brain
  - The brain helps process the image
- Rods- low light situations
- Cones- allows you to see color

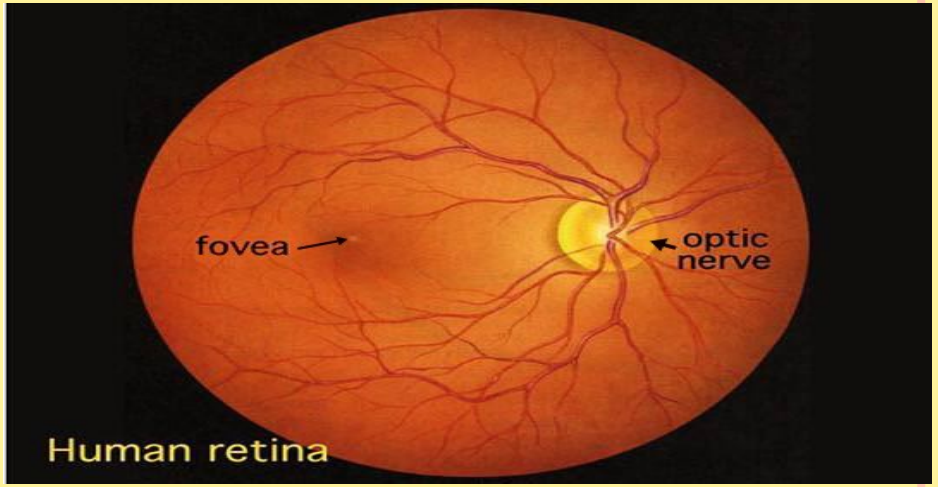

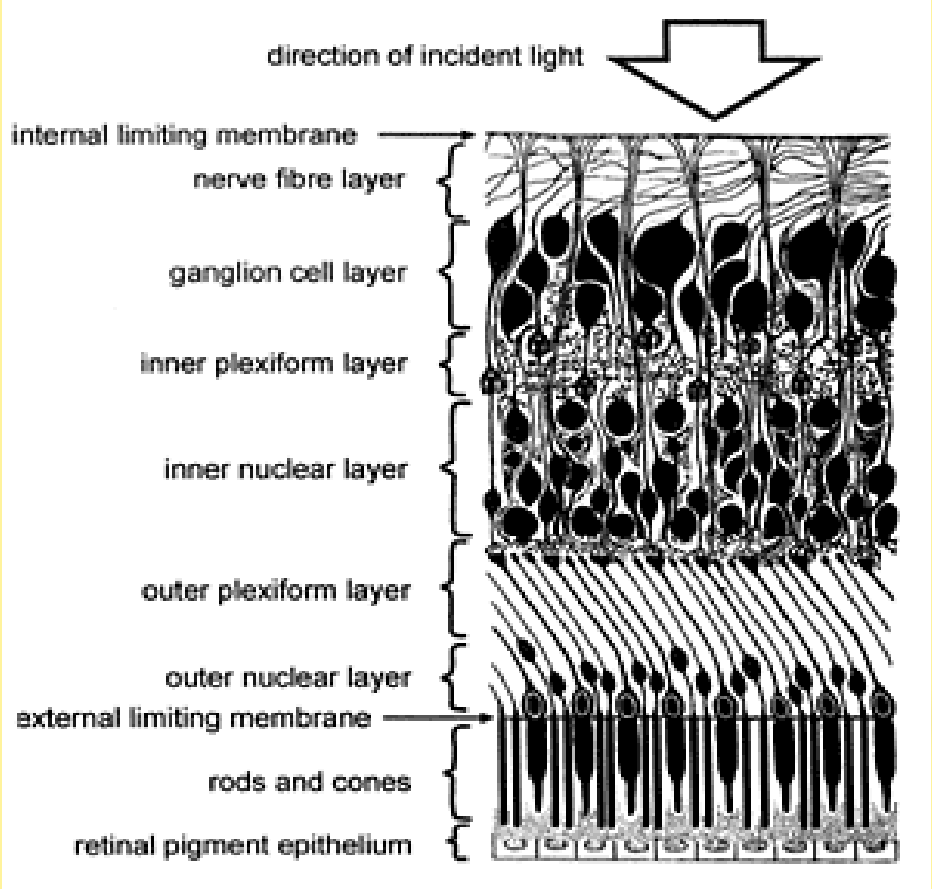

OVERVIEW

- The ability of the eye to focus on the retina depends on the length of the eye from front to back & the refractive power of the lens system
- Refraction is the bending of light rays
- Problems in either eye length or refraction can result in refractive errors

EMMETROPIA

- Its the normal refractive state of the eye. The eye acts as a convex lens and parallel rays of light are focused on the retina. Light rays coming from 6 meter or more is considered to be parallel. For this reason during distance vision testing the patient is seated 6 meters from the test chart. Most of the refraction in the eye is done by the cornea (2/3) the rest being by the lens (1/3)

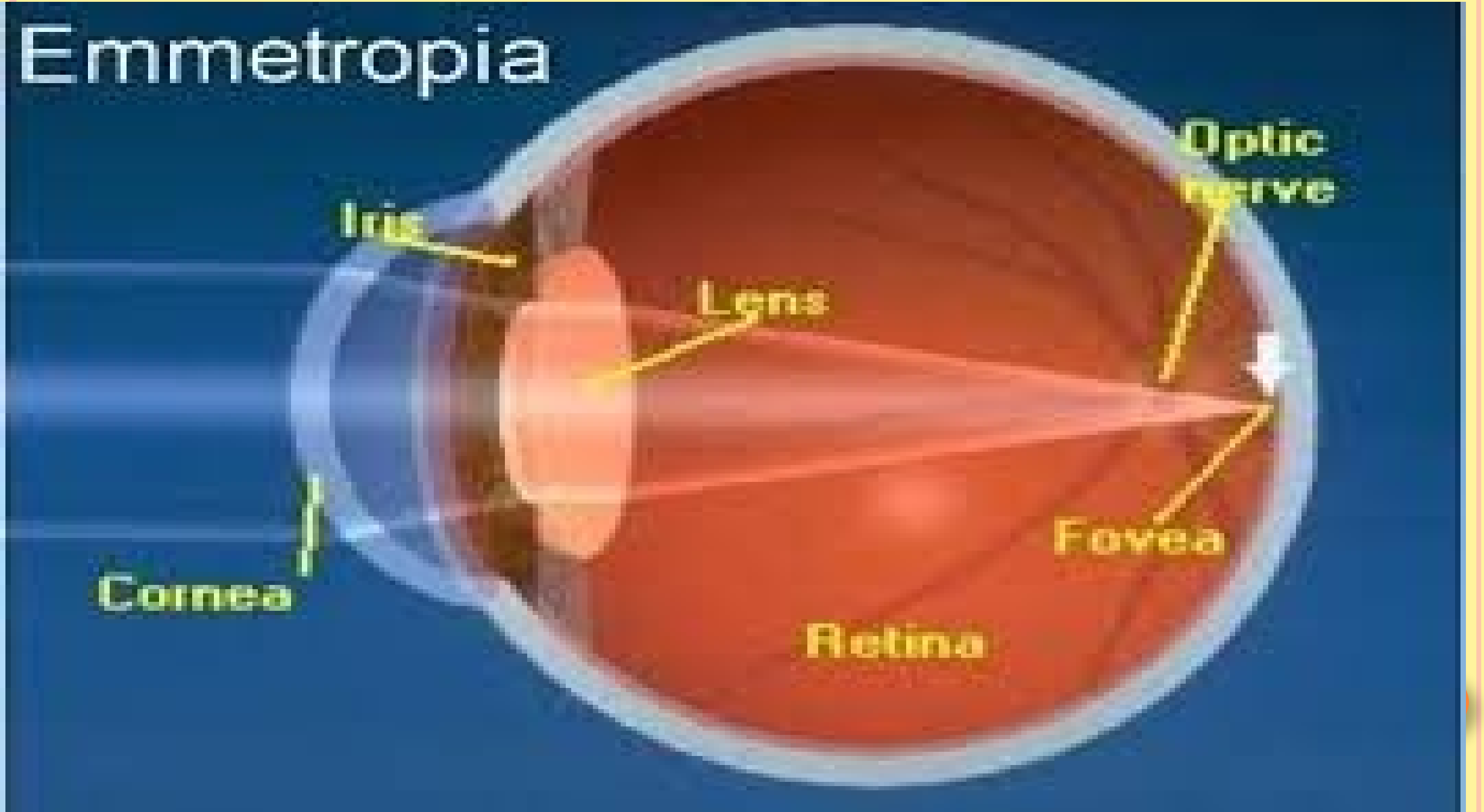
Emmetropia
Optic nerve
Iris
Lens
Fovea
Cornea
Retina

ACCOMMODATION

Rays of light from an object close to the eye is divergent and will be focused behind the retina. The eye adjusts the image by:

-Contraction of ciliary muscles thereby loosens the suspensory ligaments so that the lens will be more spherical and strong.

-Decreasing the size of the pupil.

-Contraction of the medial recti.

All these muscles are innervated by Oculomotor nerve

TYPES OF REFRACTIVE ERRORS

PRESBYOPIA

Some time after age 40, people begin to experience blurred near vision when performing tasks such as reading, sewing or working at a computer. This change is called presbyopia. There's no getting around it - presbyopia happens to everyone at some point in life, even those who have never had a vision problem before. It usually occurs at around the age of forty when people experience blurred near vision when reading or working at the computer. This is the result of the natural aging process of the lens where it becomes harder and less elastic. Accommodation will be ineffective and the person fails to do near work like reading. There is no difficulty of distant vision.

- **Treatment**-convex lens

PRESBYOPIA

- When elasticity of the lens is reduced thus accommodation
- Contraction of the cilliary muscle leads to relaxation of the lens thus more convex
- Near vision not complete

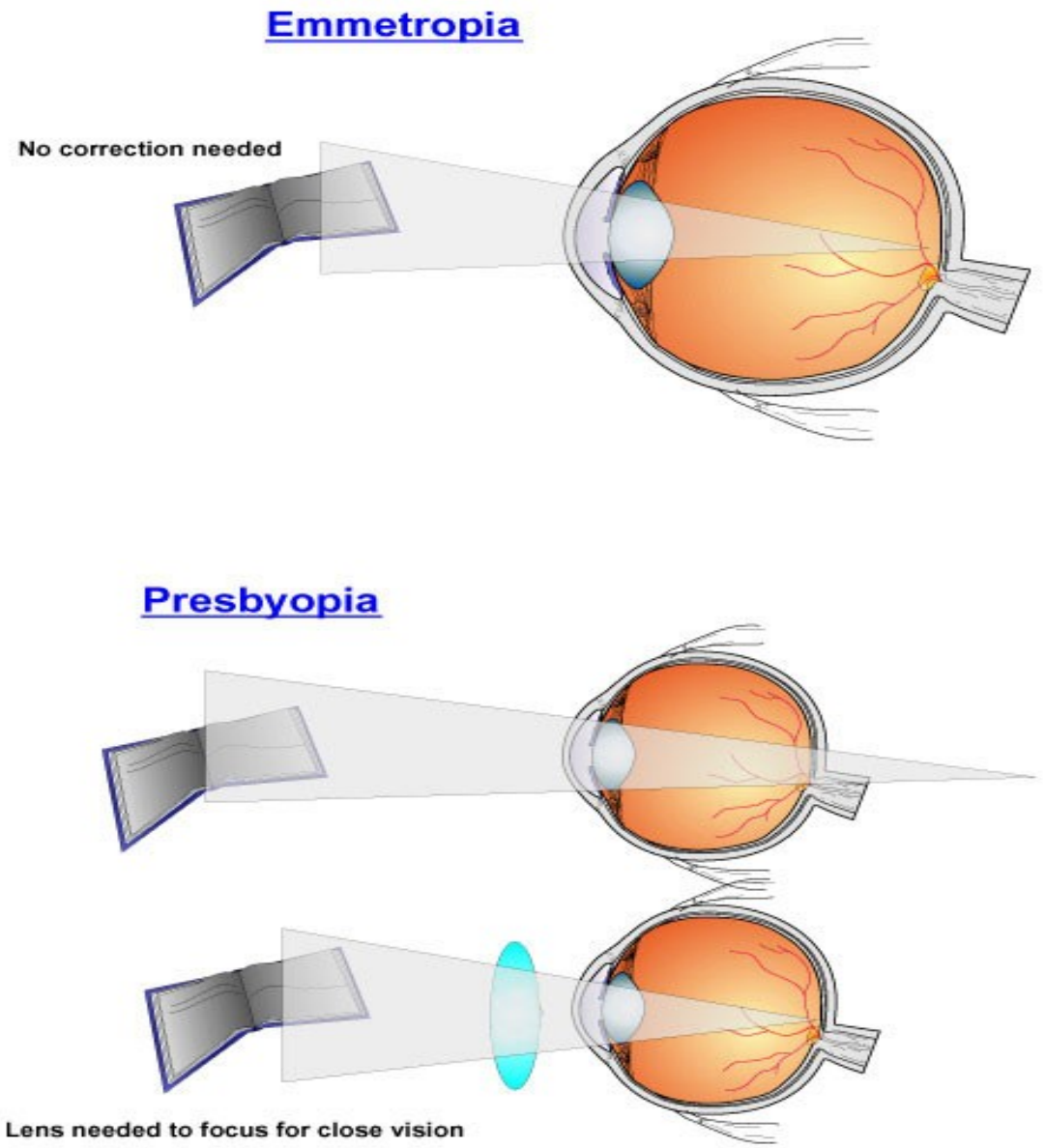

MYOPIA (SHORT SIGHTEDNESS)

- It occurs when the eyeball is too long, relative to focusing power of the cornea and lens of the eye. This causes light to be focused at a point infront of the retina rather than directly on its surface.

Symptom

- Eye strain and headaches
- -Poor distant vision
- **Treatment**
- - Spectacle- concave or negative lens

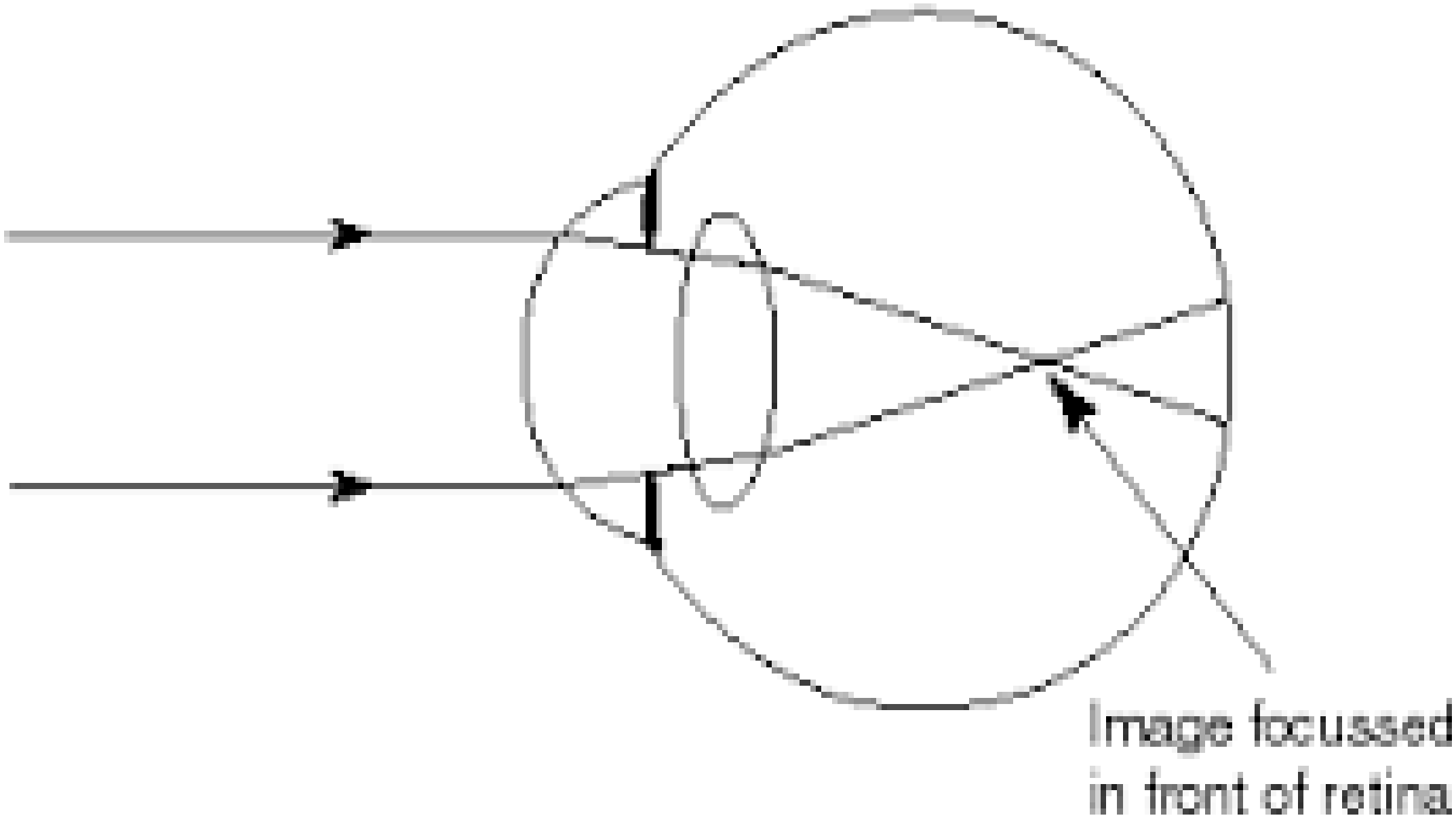
Image focussed
in front of retina

HYPERMETROPIA , HYPEROPIA (LONG-SIGHTEDNESS)

- In hypermetropia rays of light are focused behind the retina because the power of the optical system is too low for the length of the eye.

Symptoms

- -Complain about near vision tasks
- -In advanced state they will have poor distant vision

Treatment

- - Convex lens or positive lens

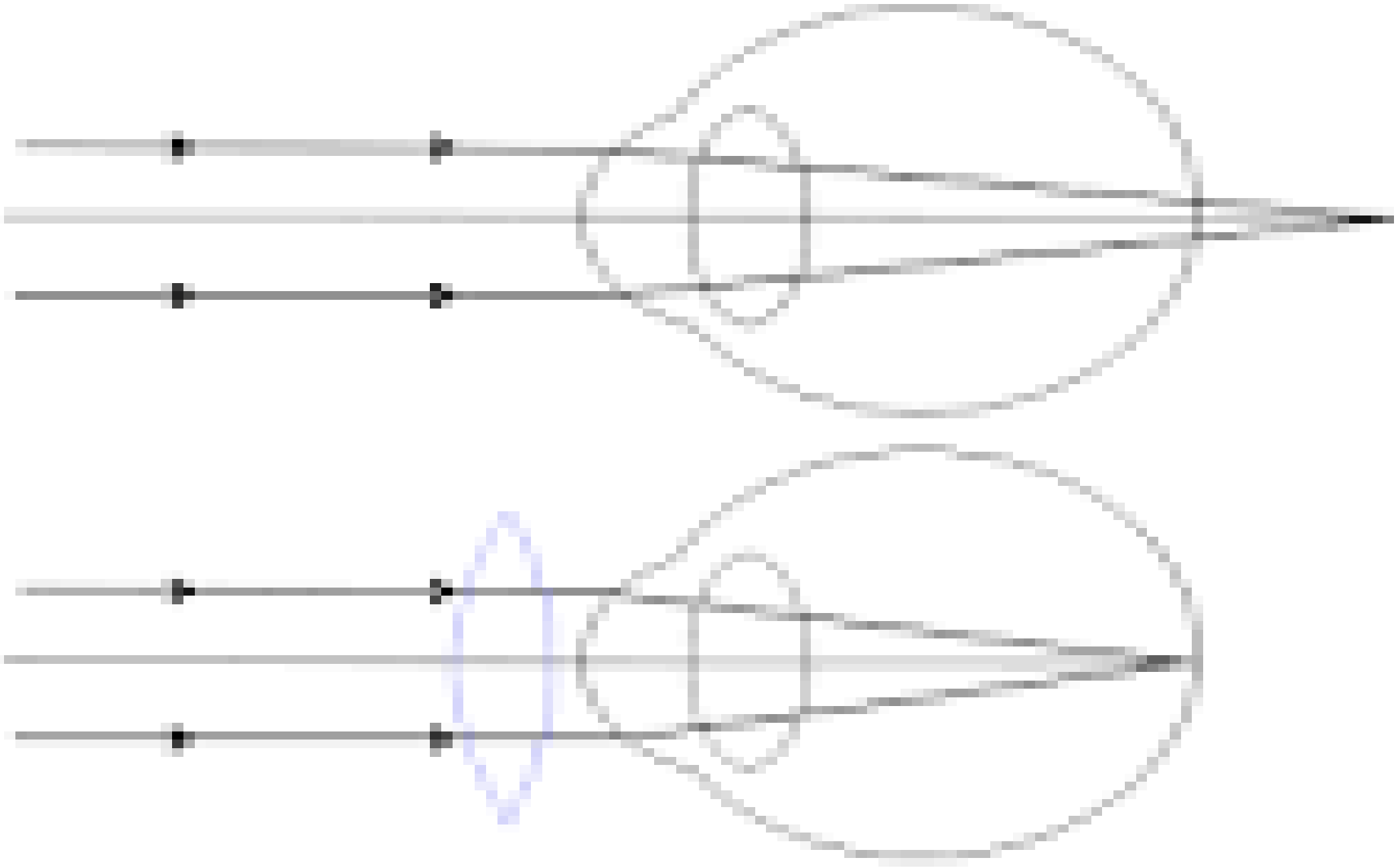

ASTIGMATISM

Occurs when the curve of the cornea is uneven because light rays are not refracted equally in all directions a focus point on the retina is not achieved

Symptom

- Distortion of image
- Poor vision at any distance

Treatment

- Spectacle with cylindrical lens

STRABISMUS

The two eyes are not properly aligned and point in different directions. It arises because of an incorrect balance of muscles that move the eye, faulty nerve signals to the eye muscles and focusing faults.

Symptom

- -Deviation of the eye
- - Could have Diplopia
- - Poor vision

Sign

- -V/A may be normal or reduced
- - Deviated eye

TYPES OF STRABISMUS

- Convergent squint – **ESOTROPIA**
- Divergent squint – **EXOTROPIA**
- Vertical squint- **HYPERTROPIA**

Squints can be divided into three groups, according to their cause

1) Congenital
2) Paralytic
3) Mechanical

Treatment

- Early detection and referral for
- - Ambylopia treatment
- - For spectacle and/or surgery

MISALIGNED EYES

- Strabismus
  - Refers to misalignment with one or both eyes turn in, out, up or down caused by muscle imbalance
  - 3 Kinds of Strabismus
    - Esotropia
    - Exotropia
    - Hypertropia
    - hypotropia

I) ESOTROPIA

Eye turns in towards nose

TYPES OF ESOTROPIA

- Infantile (congenital)
  - Develops in first 3 months of life
  - Surgery usually recommended along with vision therapy and glasses
- Accommodative
  - Usually noted around age 2yrs
  - Child typically farsighted
  - focusing to make images clear can cause eyes to turn inward.
  - Treated with glasses and vision therapy may also be needed

TYPES OF ESOTROPIA

- Partially Accommodative
  - Combination of
    - accommodative dysfunction and
    - muscle imbalance
  - Glasses and vision therapy doesn't completely correct eye turn hence surgery may be required for best binocularity

II) EXOTROPIA

- Eye turns outward; Congenital; Surgery usually needed to re-align. Many exotropias are intermittent
  - May occur when patient is tired or not paying attention
  - Concentration can force eyes to re-align
  - Vision therapy and/or glasses can help

EXOTROPIA

- When intermittent
  - Brain sometimes receives information from both eyes (binocular)
  - Less chance of amblyopia(lazy eye)

III) HYPERTROPIA

- One eye vertically misaligned usually from paresis of an extra-ocular muscle

HYPERTROPIA

There are 2 types

- Congenital (Most common type)
  - Patients compensate for years by tilting head: Can be discovered by looking at childhood photos
- Acquired
  - Trauma—Extra-ocular muscle ‘trapped’ by orbital fracture
  - Vascular infarct ;Systemic diseases affecting blood supply to nerves can cause temporary nerve palsy e.g. Diabetes and HTN most common.
  - Neurological due to a tumor (rare) or aneurysm

CONGENITAL

- Starts at birth or in early childhood. Young children do not get double vision- they suppress the image from one eye.
- Eye moves normally in all directions and the angle of the squint is the same in whatever direction the patient looks. Congenital squints may be:
- **Manifest:** present all the time
- **Latent:** only present when one eye is covered. This causes many patients who are blind in one eye to squint.

TREATMENT

Squints in children may sometimes be cured by the provision of glasses , but often surgery is required to straighten the eyes. Surgery does not affect the underlying abnormality – the inability of the brain to co- ordinate the two eyes. All squinting children should be referred, as squint may be the first sign of an underlying abnormality such retinoblastoma.

PARALYTIC

- Caused by damage to III,IV or VI cranial nerve. Damage may be due to
  1. Vascular; affecting or consisiting vessels
  2. Menengitis
  3. Tumours
  4. Trauma
- III- Pupil may be paralysed or spared. Pupil involvement suggests pressure effect and requires urgent neurological opinion.
- IV-Causes double vision looking down in adduction
- VI- Causes convergent squint and inability to abduct the affected eye. Commonest paralytic squint.

TREATMENT

- Where a cause for the paralysis is found, this should be treated . In most patients the squint gradually recovers over a period of 6 months. Any remaining squint may need to be corrected surgically. Always check for hypertension and diabetes.
- **3) Mechanical**
- Due to mechanical restriction of eye movement, usually the result of orbital disease or trauma.

DIAGNOSIS

- Forced duction test – in mechanical squint, the eye resists passive movement with a pair of forceps.
- Diagnosis and treatment are usually directed at the underlying orbital disorder. E.g. blow out fracture limited elevation of eye , following blunt trauma and accompanied by enophthalmos and anaesthesia of the cheek.

Treatment.

- Free the trapped muscles

SURGERY FOR SQUINT

- This relies on a careful measure of the angle of the squint. Resection strengthens the action of a muscle , recession weakens it. Surgery can only straighten the eyes. This may relieve diplopia in adults with paralytic or mechanical squints but is purely cosmetic in congenital squints.

AMBYLOPIA (LAZY EYE)

Definition: a reduction of vision of one or both eyes despite normal ocular finding.

Causes

- -certain types of refractive error
- - Strabismus
- -sensory e.g. cataract, Ptosis

Treatment

- - Early referral to better center

Surgical Aphakia

- This is an eye with lens removed surgically.
- Treatment-spectacle with high positive lens

STRABISMIC AMBLYOPIA

- One eye deviates from other and sends conflicting info to brain; results in under developed visual cortex for that eye. Can be reversed or decreased if treated during first 9 years
- Treatment includes visual screening
  - Vision therapy/patching
  - Glasses
  - Surgical re-alignment

ANISOMETROPIC AMBLYOPIA

- Significant difference between both eyes
- Commonly one eye more farsighted and works harder to see clearly and sometimes gives up
- If not caught, one eye won’t learn to see as well as other
- Vision therapy and glasses are both beneficial

DEPRIVATIONAL AMBLYOPIA

- Any opacity in visual pathway can be devastating to developing visual system
  - Congenital cataracts
  - Corneal opacities
  - Ptosis (droopy eyelid)
  - Other media opacities

GLAUCOMA

ANATOMY REVIEW……..INTRAOCULAR PRESSURE

INTRODUCTION;

Normal Intraocular pressure = 12 – 20 mmHg. It is largely depended upon the structures within the eyeball, but especially the **aqueous** humour.

Factors that maintain normal IOP:

-Rate of formation of Aqueous humour

-Rate of drainage of AH through trabecular mess

- Pressure in the episcleral veins(Sinus Venosus Sclerae) in which canal of Schlemm drains

- Elasticity of the cornea and sclera- remain constant

THE AQUEOUS HUMOUR

Is transparent fluid. Produced by the epithelium cells of the ciliary body into the posterior chamber, between the lens and the iris.

It circulates through the pupil to the anterior chamber.

It is then absorbed into Sinus Venosus Sclerae after passing through the canal of schlemn at the angel of filtration (where the posterior surface of the cornea joins the iris).

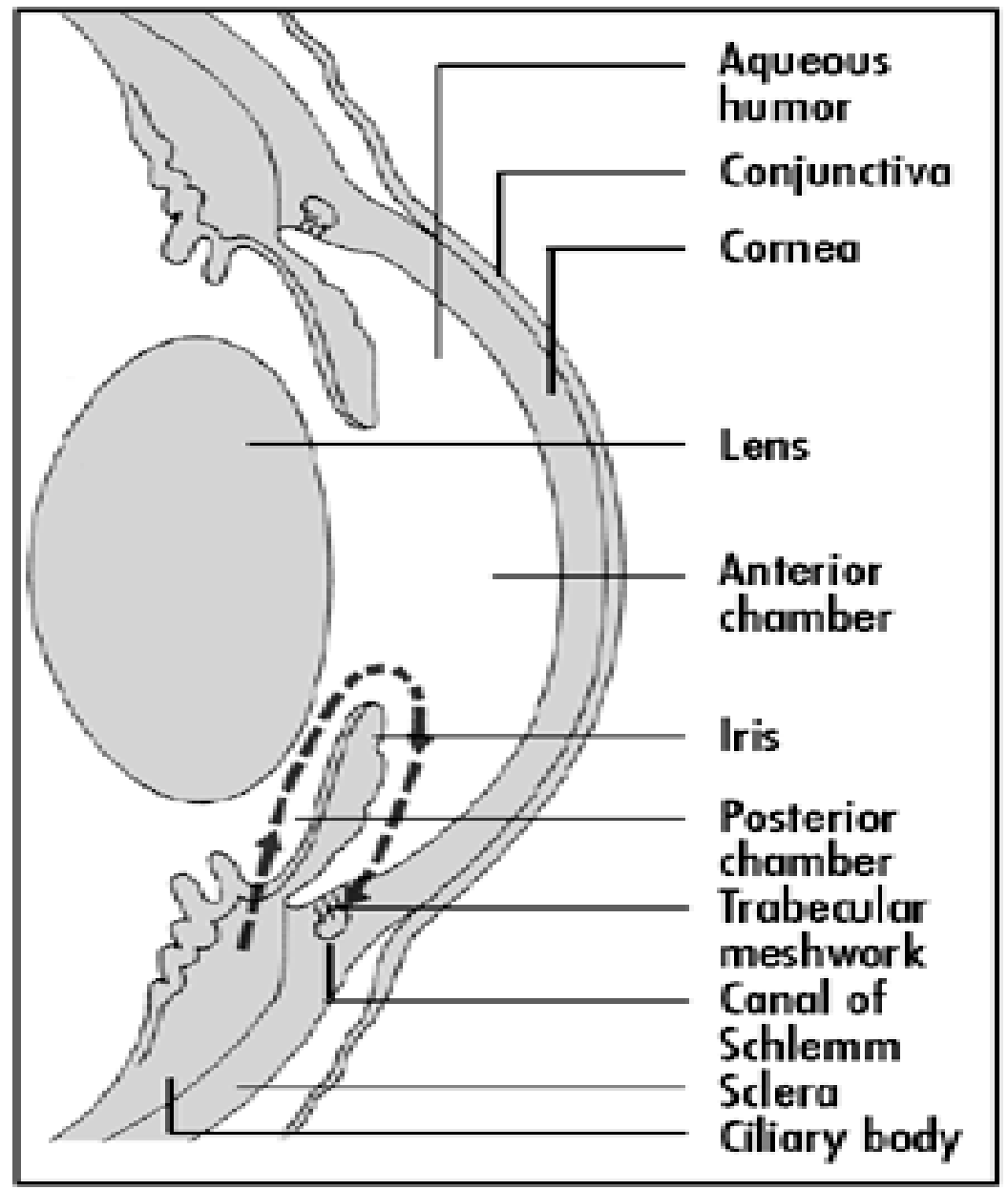

THE AQUEOUS HUMOUR

From the Sinus Venosus Sclerae it enters the general circulation.

The trabecular muscle at the angle of filtration controls passage

of humour to the canal of schlemn

The aqueous fluid varies according to:

- Rate of production
- Rate filtration .

If excessive production – glaucoma (rare)

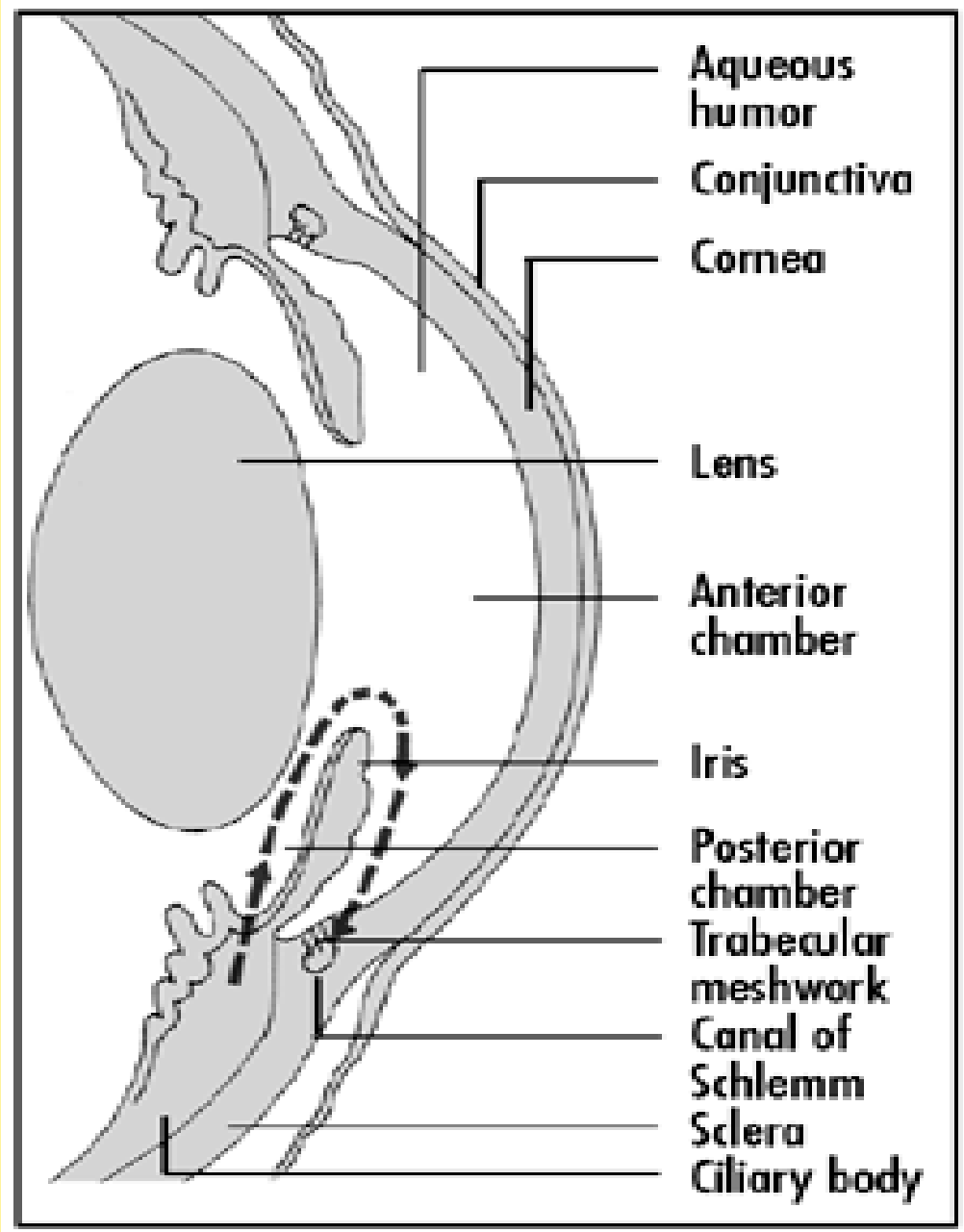

INTRODUCTION

Glaucoma is a group of ocular conditions characterized by **optic nerve damage**. The optic nerve damage is related to the raised intraocular pressure which results from a blockage in the flow of aqueous from the ciliary body to the trabecular meshwork. This damages the fibres of the optic Nerve, causing optic atrophy,and loss of vision. In addition it may cause corneal oedema and iris atrophy.

CLASSIFICATIONS OF GLAUCOMA

1. *Open-angle glaucoma*
2. *Closed angle glaucoma*.
3. Secondary/ normal tension glaucoma
4. Congenital mostly in children

Others; Pigmentary glaucoma

OPEN ANGLE GLAUCOMA /CHRONIC GLAUCOMA

Its caused by the Obstruction to the aqueous outflow due to defect in the drainage mechanism(the block is in juxtacanalicular trabecular tissues whereby collagen content of the trabecular fibres become increased blocking the pores of meshwork

- Most common cases which present with this type are usually hereditary
- Haemorrhage (clot) of the passage can also cause this type

RISK FACTORS

- Age more common in those over forty years due to shrinkage and narrowing of the trabecular meshwork
- Intraoccular pressure
- Corticosteroids medications
- Medical problems e.g. diabetes, migraine headaches, hypertension.
- Eye abnormalities.
- Race its more common in Africa
- Family history
- Lifestyle e.g. smokers, alcohol intake, obesity.

CLINICAL FEATURES

1. Initially it is asymptomatic No pain. No redness. No irritation. Then the patient is slowly losing sight and requires change of glasses frequently.

2.Then loss of visual field. Visual field is the entire areas that can be seen without shifting the eye. He sees only what is in front of him and not what is sideways.

CLINICAL FEATURES CONT……

3. Cupping of the optic disc. There is thrombosis of the retinal veins. They seem to be lying deep inside the disc, due to direct pressure on the optic nerve. (Thro fundoscopy)

DIAGNOSIS

- Tonometry - IOP
- Opthalmoscopy
- Genioscopy
- Fundoscopy – Cupped Optic
- Perimetry Visual Fields↓

MANAGEMENT

Medical (drugs) treatment to control the pressure is the treatment of choice;

- Pilocarpine eye drops 0.25% - 0.5% 2 hourly- It is miotic.

Facilitates aqueous out flow. The smaller the pupil the thinner the iris, therefore giving more space for drainage of aqueous at angle of anterior chamber. It also reduces the formation of aqueous humour

- Eserine sulphate 1% - ½ hourly. May also be used. (It is more powerful) but usually avoided because it is irritating..

MEDICAL (DRUGS) TREATMENT

- Adrenaline 1% eye drops (here it is a vaso constrictor) it decreases rate of aqueous formation.

or

- Timolol (beta blocker) 0.25% - 0.5%.-suppress aqueous production

- Diamox tabs 250-500mgs tds x 3/7-diuretic effect

NB These drugs may be used alone or in combination

If no improvement, ON Medical Treatment then surgery = TRABECULECTOMY.

In this operation the acqueous humour is made to drain through sclera

PRE OPERATIVE PREP. FOR TRABECULECTOMY.

- General pre operative care……
- Patient is reassured.
- Patient explained that surgery will not improve sight but will prevent it becoming worse Conjuctival swab for C/S..
- Any infection, cough, constipation is treated before surgery .
- Better diet.

POST OPERATIVE CARE FOLLOWING TRABECULECTOMY

- General post operative care……..
- The operated eye to remain covered for 5/7 .
- Patient to lie on back with as many pillows as he/she likes.
- To be fed in bed for atleast two days to enhance rest.
- Conjuctiva stitch on 5th day.
- Clean eye gently tds with N/saline and check for any abnormality.
- On discharge patient advised against sudden heavy exertion. To be followed closely in clinic.

CLOSED ANGLE GLAUCOMA OR ANGLE CLOSURE OR NARROW ANGLE GLAUCOMA

Its common in older people ages 50 – 60 years due to a shallow anterior chamber causing obstruction to the drainage areas by the base of the Iris. The iris tissue narrows the anterior chamber. Thus pressure increases in anterior chamber.

CLOSED ANGLE GLAUCOMA OR ANGLE CLOSURE OR NARROW ANGLE GLAUCOMA

Cause

- Age because the lens inside our eyes gets larger increasing the risk for pupil block
- Race common in Asians because they have narrow anterior chamber angles
- Sex common in women than men but cause is unknown.

CLINICAL FEATURES

Of sudden onset.

- Blurring vision.
- Corneal oedema

May progress to an attack of acute glaucoma where by the patient presents with:-

- Severe eye pain and vomiting.
- Very red eye
- Pupil fixed and dilated
- Rapid loss of vision

NB: Should be treat as emergency

MANAGEMENT

If acute symptoms develop then:-

- Patient started on I.V manitol 150 mls 60 drops per minute.
- I.V Diamox 500 mgs diluted in 10 cc Normal saline – stat then oral 250 mgs 250 mgs tds to control pressure.
- Pilocarpine drops 0.25% - 0.5% 1 – 2 hourly. Patient is monitored closely – i.e. visual fields & IOP
- To prevent another attack – surgery – **Peripheral Iridectomy**

PERIPHERAL IRIDECTOMY

- This operation is done after the pressure has been reduced (lowered) by medical therapy.
- It is advisable to do the same operation on the other eye as a prophylactic measure.
- Specific pre operative and post operative as for tuberculectomy

SECONDARY GLAUCOMA

- Caused or secondary to other eye diseases e.g. trauma, iritis

Treatment

- Treat the cause.
- Control pressure by Diamox tabs 250 mgs tds
- Pilocarpine eye drops. Then the patient is followed by closely in the clinic as may need surgery

CONGENITAL GLAUCOMA (BUPHTHALMOS)

Cause

- Maldevelopment of Trabecular muscle or canal of schlemn so that drainage system is poor.

CLINICAL FEATURES

- Infant has large, grey eyes.
- Photophobia: (he protects his eyes from light).
- Usually bilateral.
- Deep anterior chamber → The corneal diameter is larger than normal.

MANAGEMENT

Surgery

Either

- **Goniotomy**

A needle is inserted and rotated into an angle of filtration to widen or open the blockage.

OR

- **Trabeculectomy**

UVEITIS

It’s the inflammation of the uveal tract – iris, ciliary body or choroid. Uveitis can have a more insidious onset and can involve any portion of the uveal tract

CAUSES

- Infections
- Trauma
- Sympathetic inflammation
- Autoimmune

CLINICAL FEATURES

- Severe pain in eyeball radiating to the forehead and temple.
- Photophobia
- Lacrimation
- Blurred vision
- Oedema of eyelids’
- Swollen discoloured iris
- Pupil is constricted

TYPES

1. NONGRANULOMATOUS

It’s the most common type.

It manifests as an acute condition with pain, photophobia and a pattern of conjunctival injection, especially around the cornea. The pupil is small or irregular and vision is blurred.

There may be small, fine precipitates on the posterior corneal surface and cells in the aqueous humor (ie, cell and flare). If severe, a **hypopyon** (ie, accumulation of pus in the anterior chamber) may occur.

CONTD…

The condition may be unilateral or bilateral and may be recurrent.

Repeated attacks of nongranulomatous anterior uveitis can cause anterior synechia (ie, peripheral iris adheres to the cornea and impedes outflow of aqueous humor). The development of posterior synechia (ie, adherence of the iris and lens) blocks aqueous outflow from the posterior chamber. Secondary glaucoma can result from either anterior or posterior synechia. Cataracts may also occur.

GRANULOMATOUS

It’s also called the anterior uveitis.. It tends to be chronic.

Pathophysiology

Mostly it may result from an autoimmune reaction or from the hosts immune response to a systemic infectious process e.g. syphilis or TB. They reflect an inflammatory response that implies a chronic inflammation Uveitis can have a more insidious onset and can involve any portion of the uveal tract.

SYMPTOMS

- Photophobia and pain may be minimal.
- Vision is markedly and adversely affected.

Conjunctival injection; bloodshot eyes is diffuse and there may be vitreous clouding. In a severe posterior uveitis, such as chorioretinitis, there may be retinal and choroidal hemorrhages.

SIGNS

- Red marks at limbus.
- Keratic precipitates - spots on posterior Surface of cornea, caused by inflammatory cells sinking through the aqueous and sticking to the cornea.
- Hypopyon – it’s a whitish area inside the eye infront of the lower part of the iris which is pus formed by inflammatory cells collecting in the inferior part of AC.
- Posterior Synechiae - pupil has irregular shape.
- Vitreous cells – visible as tiny floating dots against the red reflex.

RISK FACTORS

- Genetic predisposition
- Infections like TB, toxoplasmosis etc.
- Having an autoimmune or inflammatory disorder.
- History of trauma.

MANAGEMENT OF UVEITIS

The systemic disease should be treated with appropriate drug/antibiotics.

- Pus swab C/S to aid in treatment
- Reassure the patient..
- Clean eye with N/saline tds or frequently and apply antibiotics eye ointment e.g. 1% tetracycline tds
- Systematic antibiotics e.g. IM crystapen 2 mega units 6hrly x 7- 10 days
- Atropine sulphate 1% to diminish congestion. It will also prevent adhesion formation.
- Keep eye padded or patient can use dark glasses.
- Complete bed rest during the acute phase.

MNGT……CONTD

- Analgesics for pain e..g panadols 2 tabs prn
- Apperient to prevent constipation.
- Improve diet – vitamin A,B and C
- Observe:-

  – general state of the eye as you clean – e.g. check for Hyphema (blood in the anterior chamber)

  - General state of patient

  - Vital signs and BP 4 hourly

COMPLICATIONS

- Adhesions – iris may stick to lens
- Keratitis
- Secondary glaucoma
- Blindness

SYSTEMIC DISEASES AND THE EYE

DIABETIC RETINOPATHY

DEFINITION

- Diabetes causes damage to blood vessels in the retina, which may lead to loss of vision.

RISK FACTORS

- People who have had diabetes for a long period.
- Diabetics with high blood pressure.
- People with high sugar levels.
- Poorly managed diabetes.
- Diabetics who become pregnant.

SYMPTOMS

- Blurred, distorted or patchy vision that can’t be corrected with glasses.
- Problems with balance, reading, watching television and recognizing people.
- Overly sensitive to glare.
- Difficulty seeing at night.

TREATMENT

- Annual eye checks to pick up early signs of damage.
- Control blood-glucose levels and make sure the diet is low in fat.
- Once vision has been affected, seek treatment to prevent progression.

CONTD…

Prevention of blindness in diabetics

DM is the leading cause of blindness in some third world countries, however, it is preventable. Firstly, DM is often caused by obesity, which can be avoided. Secondly all diabetic patients should have an annual eye examination, with dilated pupils. Anyone with any retinopathy should be sent to an ophthalmologist for evaluation.

AIDS AND THE EYE

AIDS is a disease caused by infection with the retrovirus HIV, or Human Immunodeficiency Virus. The virus attacks the lymphocytes that protects us from infections and cancers, and the patient dies from infectious disease or malignancy. The virus is carried in the blood stream, and is spread mainly by sexual contact, but also by blood transfusion, or by needles or other instruments contaminated by infected blood.

OPHTHALMIC MANIFESTATION IS CLASSIFIED AS

- Microvasculopathy
- Tumor e.g. Kaposi’s sarcoma, Squamous cell carcinoma
- Neuro-ophthalmopathy e.g. cranial nerve palsy, optic atrophy
- Opportunistic infection e.g. herpes zoster ophthalmicus, herpes simplex infection, toxoplasmosis etc

A. OPPORTUNISTIC INFECTIONS

1. OPHTHALMIC HERPES ZOSTER

- Its caused by varicella zoster
- The eye is affected through ophthalmic branch of trigeminal nerve.
- Its Unilateral
- Common in immunocompromized patient
- 90% are sero positive for HIV infection.

SYMPTOMS

- Prodromal symptoms of URTI
- The rash appears 2-3 days after the pain,
- The rash is not different in sero positive and sero negatives but recurrent in sero positives

SIGNS

- Maculopapular rash in the forehead
- Development of vesicles, pustules and crusting ulceration
- In severe cases – periorbital edema due to secondary bacterial cellulitis.
- It can also cause Keratitis, Uveitis, Keratouveitis, cataract, vitritis etc

TREATMENT

Analgesics e.g. Paracetamol

- *Gentian violet*– 0.5% to clean the wound
- *Topical antibiotics to the eye*

Antiviral e.g Acyclovir 800mg 5x/day/for 7days

It should be given within72 hrs after rash because the drug needs active viral replication

- Refer to ophthalmic center for further evaluation.

2. MOLLUSCUM CONTAGIOSUM

Uncommon skin infection caused by a poxvirus. It is common in children and immunocompromized patient. In immunocompromized patient, it is multiple, large size, bilateral, recurrent and resistant to treatment skin lesions.

Symptom – painless, raised, skin lesion.

Sign

- Single or multiple
- Pale, waxy
- Umblicated nodules

If the nodule is located on the lid margin it may give rise to ipsilateral chronic follicular conjunctivitis and occasionally a superficial keratitis

TREATMENT

- Drainage
- Shaving and excision
- Destruction of the lesion by cauterization, cryotherapy

B. TUMOURS

1. SQUAMOUS CELL CARCINOMA

- A malignant neoplasm of keratinizing cells of the epidermis with high chances to metastasize

Symptoms and signs

- - Painless plaque or nodule with variable degree of scale, crust and ulceration

Treatment

- - Referral for surgical excision and biopsy

2. KAPOSI'S SARCOMA

- Its a malignant vascular tumor that develops on the skin, mucous membrane, lymph node and visceral organs.
- It appears like flat or raised non tender , purple red -dark reddish lesion over the eye lid or conjunctiva.
- Referral for surgical excision and biopsy.

C. MICROVASCULAR

1. HIV RETINOPATHY

It is a non-infectious micro vascular disorder characterized by cotton wool spots, micro aneurrysm, retinal hemorrhages and area of capillary non-perfusion. These micro vascular changes are the most common retinal manifestations of HIV disease and are clinically apparent in about 70% of persons with advanced HIV disease.

D. NEURO OPTHALMOPATHY

CRANIAL NERVE PALSY

- If the third, fourth, or sixth nerves are affected, there will be diplopia. If optic nerve is affected, there will be loss of vision.

Causes : CMV or other infections

Diagnosis

- -serology (ELISA)for HIV
- - Clinical

Treatment

- -Treatment of opportunistic infection accordingly
- -Antiretroviral drugs
- -Health education about the syndrome

TRAUMA

- Usually presents as a unilateral red eye with a history of injury

FOREIGN BODY

- Most foreign bodies are washed out by the patients own tears.
- Sub- tarsal foreign bodies lodges in tarsal sulcus in upper tarsal conjunctiva. Blinking scratches the cornea, causing a characteristic linear staining pattern with fluorescein.
- Remove by reverting upper lid and wiping with cotton wool.

CHEMICAL INJURIES

- Many chemicals will cause transient pain and redness if they go into the eye.
- The chemical likely to cause blindness is alkali e.g. washing soda, lime , ammonia.
- Alkalis penetrate the cornea and sclera, causing severe uveitis, necrosis of the cornea, secondary glaucoma and blindness.

TREATMENT

1. Immediate and very thorough irrigation with water.
2. If the injury is severe, give antibiotic, atropine, steroids and refer urgently.
3. Effective treatment if alkali burns is very difficult, so these injuries must be prevented by proper education of people exposed to dangerous chemicals and by the provision of suitable safety glasses.

RADIATION INJURIES

- **Visible light** -Exposure of the eye to a flash from a welder causes a very painful superficial punctuate keratitis.
- **Ultra violet light** - Strong light can damage the retina. If a patient looks at the sun for a long time, the macula can be permanently burned e.g. solar eclipse.

SIGNS AND SYMPTOMS

1. The patient presents with severe pain
2. Photophobia which usually occurs a few hours after exposure, and resolves within 24-28 hours.

TREATMENT

- Atropine
- Antibiotic
- Eye pad.

IONISING RADIATION

- Exposure causes cataracts.
- High doses as in radiotherapy can:
  - Damage the retina and optic nerve.
  - May cause a dry eye.
  - Symbelpharon ;adhesion of the eyelid to the eyeball.
  - Corneal scarring.

PENETRATING INJURY

- Penetrating injury is a significant cause of blindness worldwide. Blindness results from:-

1) Damage to and loss of ocular contents
2) Infection

In Many injuries, blindness is preventable by good first aid and prompt referral.

CAUSES OF PENETRATING INJURY

The two common causes are:-

1. Cutting wood
2. Thorns going in the eye while working in the field

Always suspect a penetrating injury if there is a history of injury with a small fast object or sharp object.

ON EXAMINATION

- CORNEA – May have a large laceration, or a small opacity at the site of the puncture wound.
- SCLERA – Scleral wounds are less common than corneal. They are more serious as there is often prolapse of vitreous and retina
- Anterior C – Often deep if there is a small wound in the cornea, or if the laceration is plugged with iris.
- Will be shallow if the lens is intumescent, or if aqueous is escaping through the wound.
- If there is a large corneal wound, and a hyphaema, this usually indicates very serious damage to the eye.

ON EXAMINATION…CONTD

- **Iris and pupil** – The Iris may prolapse through a large wound, distorting the pupil. There is always an intense uveitis, and neglected cases may have small irregular pupils with dense posterior synechiae.
- **Lens** – In a severe injury the lens may be expelled from the eye. More commonly there is a traumatic cataract, caused by penetration of the lens capsule, the lens rapidly opacifeies and swells. Soft lens matter may escape into the AC causing a Phacolytic uveitis.

MANAGEMENT OF PENETRATING INJURY

- Immediate referral to an eye surgeon is the first priority.
- Examining a lacerated eye may cause more damage. As soon as you have made the diagnosis of penetrating injury, no further examination is needed.
- Early surgery, with repair of the wound and cataract extraction can often restore useful vision.
- Infection should be prevented with topical antibiotics, and tetanus prophylaxis.
- The uveitis should be treated with atropine.
- The eye should be protected with a pad and shield.
- If the eye cannot be repaired, or has become infected, then it should be eviscerated, to prevent spread of infection and sympathetic ophthalmia

Remember:

H – History

A - Atropine

T - Tetanus prophylaxis

A - Antibiotics

R - Refer

I - Immediately

INTRA- OCULAR FOREIGN BODY

- Small chips of metal may fly off at high speed when one piece of metal is being hammered with another. Jua kali workmen are particularly at risk.
- There will be a small entry wound in the cornea, and usually a tiny hole in the iris.
- There is usually a cataract, but it may be localised to the track of the metal fragment
- If the IOFB remains in the eye, it can cause death of the retinal photoreceptors, as a result of the high concentration on iron in the metal.
- Patients with IOFB should have an X –ray of their orbits to show the FB, and should be referred for removal of the FB

BLUNT TRAUMA

- Blunt trauma is usually caused by a large relatively slow moving object, such as a fist or a stone. All parts of the eye may be affected by blunt trauma. If you find any type of injury, there will often be other injuries present as well.

LIDS

- Because of the loose tissue in the lids, bruising causes a large, tense periorbital haematoma.
- It may be impossible to open the eye and Its best to leave the eye until the swelling subsides after a few days

Conjunctiva

1. Blood may collect under the conjunctiva – sub- conjunctival haemorrhage. This may look serious but is actually harmless and disappears without any treatment.
2. They frequently occur without any history of trauma and are of no significance.

CORNEA

1. The commonest form of blunt trauma is corneal abrasion.
2. The corneal epithelium is scraped off, leaving an ulcer.
3. The eye is painful and photophobic there is ciliary injection and the abrasion stains with fluorescein.

Anterior chamber

- Following blunt trauma, blood vessels in the angle may be damaged and there is bleeding into the AC. Blood in the AC is called Hyphaemas.
- Small hyphaemas(less than 1/3 of the AC) are not serious.

CONT,D.

1. Larger ones may bleed again 24-48 hours after the injury. Secondary bleeding tends to fill the whole AC with blood, and causes severe secondary glaucoma.
2. Small hyphaemas do not require any treatment, but patient with larger hyphaemas should be admitted and put on strict bed rest.
3. Total hyphaemas with secondary glaucoma, need to be removed urgently, to prevent blood staining of the cornea and optic atrophy